



Kidney infarction in patient with covid-19: clinical case

Infarto renal en paciente con covid-19: caso clínico

Georgina Gentili,¹ Pablo Leonardo Pérez,¹ Ezequiel Laplumé-Elizalde,¹ Sebastián España.¹

Abstract

Description: A 50-year-old male who was admitted to intensive care with a Coronavirus-19 diagnosis for strict handling requiring oxygen therapy. He presented distention and abdominal pain, for which an abdomen-pelvic tomography was requested, reporting lack of filling in the right renal artery and renal infarcts requiring angioplasty and double antiplatelet therapy. The evolution was favorable, and the patient was discharged. Currently, a renal Doppler reports adequate vascularization. The patient presents proper renal function.

Clinical Significance: The coronavirus disease is a contagious and life-threatening infection caused by the severe acute respiratory syndrome coronavirus 2. It can lead patients to arterial and venous thrombosis. However, acute renal artery occlusion is considered a rare disease.

Clinical Implications: Prompt diagnosis and treatment are important to prevent permanent kidney damage or permanent loss of kidney function.

Conclusion: The underlying etiology of renal infarcts remains largely unknown at present, but it may include direct viral cytopathic effects on endothelial cells. Most patients are managed conservatively. Some cases undergo angioplasty successfully. The patient in this case received earlier treatment with doses of anticoagulant enoxaparin, and his glomerular filtration remained stable, although complementary treatment was required.

Keywords:

COVID-19 disease,
Renal Infarct,
Coagulopathy, Renal
artery thrombosis,
Angioplasty

Corresponding author:

*Georgina Gentili.
Sanatorio San José,
Buenos Aires. PC 1425,
Sánchez de Bustamante
1674, Buenos Aires,
Argentina. Correo
electrónico:
gentiligeorgina@gmail.
com

Citation: Gentili G., Pérez P. L., Laplumé-Elizalde E., España S. *Infarto renal en paciente con covid-19: caso clínico. Rev Mex Urol. 2022;82(1):pp. 1-8*

¹ Sanatorio San José, Buenos Aires, Argentina.

Received: 11 de junio de 2021
Accepted: 29 de noviembre de 2021



Resumen

Descripción: Masculino de 50 años que ingresó a terapia intensiva con diagnóstico de COVID-19 para manejo estricto con requerimiento de oxigenoterapia. Intercurrió con distensión y dolor abdominal, por lo que se solicitó tomografía de abdomen-pelvis informándose falta de relleno en arteria renal derecha e infartos renales con necesidad de angioplastia y doble antiagregación. Evoluciona favorablemente y se otorga el alta. Actualmente, el Doppler renal informa adecuada vascularización. El paciente se encuentra con buena función renal.

Relevancia: La enfermedad por coronavirus es una infección contagiosa y potencialmente mortal causada por el síndrome respiratorio agudo severo coronavirus-2. Puede predisponer a los pacientes a trombosis arterial y venosa. Sin embargo, la oclusión aguda de la arteria renal es una enfermedad poco común.

Implicaciones clínicas: Es importante un diagnóstico y tratamiento rápido para prevenir la pérdida o daño renal permanente.

Conclusiones: Los mecanismos subyacentes de los infartos renales en gran parte son desconocidos, pero puede incluir efectos citopáticos directos del virus en las células endoteliales. La mayoría de los pacientes se tratan de forma conservadora. Algunos casos se someten a angioplastia con buenos resultados. Nuestro paciente mantuvo estabilidad del filtrado glomerular y fue tratado precozmente con dosis anticoagulantes de enoxaparina, aunque requirió tratamiento complementario.

Palabras clave:

Enfermedad por COVID-19, Infarto renal, Coagulopatía, Trombosis de arteria renal, Angioplastia.

Background

A 50-year-old male who had no drug-allergy history was reported, but he did report a surgical history of cholecystectomy, and traumatic surgery of the right tibia-fibula. The patient didn't report any clinical history or regular medication.

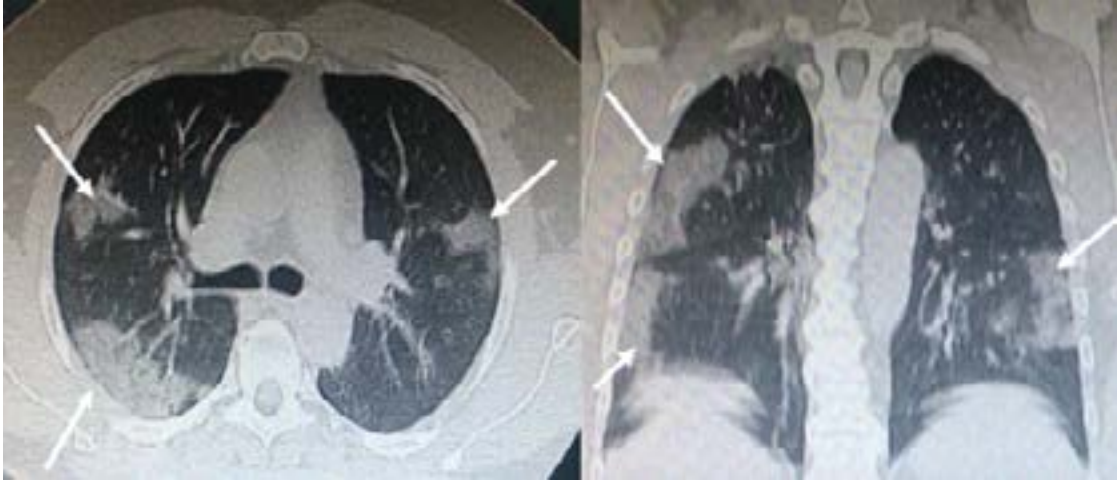
Clinical case

The patient had a previous consultation on 08/09 in another health center, showing symptoms of general malaise, myalgia, dry cough,

anosmia, dysgeusia, dyspnea, and fever of 39°C, within a 4-day process. A nasopharyngeal swab was performed, and it was positive for SARS-CoV-2. On 08/12, he was transferred to the Intensive Care Unit, presenting HR 115 bpm, RR 24 bpm, BP 120/75 mmHg, temp. 36 degrees, and 90% on room air saturation with a requirement of oxygen therapy.

Ground glass opacities on chest computed tomography (CT) and bilateral infiltrates with a tendency for consolidation (Fig. 1). The patient signed an informed consent to receive plasma transfusion.

Figure 1: Bilateral, subpleural ground-glass opacities suggestive of SARS-CoV-2 pneumonia



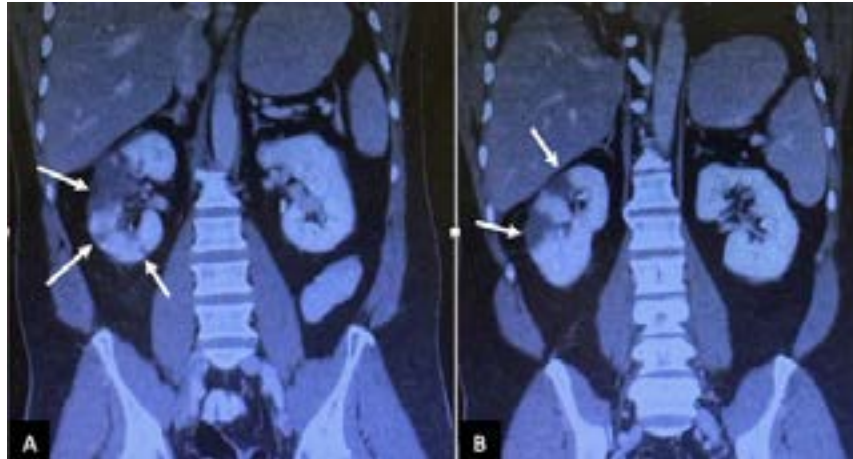
Upon admission, blood cultures x2 (HMC) and urine culture (UC), central line placement and right radial mean arterial pressure (TAM) were performed. Antibiotic treatment began with clarithromycin and ceftriaxone, dexamethasone and enoxaparin, 0.4cc every 12hs.

Laboratory admission: RBC 39, Hemoglobin 13, WBC 15.5 (4.5 to $11.0 \times 10^9 / L$), Platelets 155, PT 95, APTT 35, BG 150, U 26, Creatinine 0.6, Ferritin 1361 (12 - 300 ng / mL), Fibrinogen 574 (200 - 400 ng / mL), D-Dimer 270 (up to 500 μ g / L), Troponin <40 (up to 0.04 ng / mL), Na 140, K 3.6, Cl 103, CPK 267 (32 - 294 U / L), PCR +. Ca 1.12, Phosphate 2.4, Magnesium 2.4, TB 0.38, DB 0.15, ALP 92, GOT 47, GPT 143, Ac. Uric 2.4, LDH 685 (105 - 333 U / l). ABS: Ph 7.45, PCO₂ 37.9, PO₂ 74.6, HCO₃ 25, BE 1.6.

On 08/15, the patient reported lower right limb pain with variable temperature, a Doppler ultrasound was performed showing negative results for deep vein thrombosis.

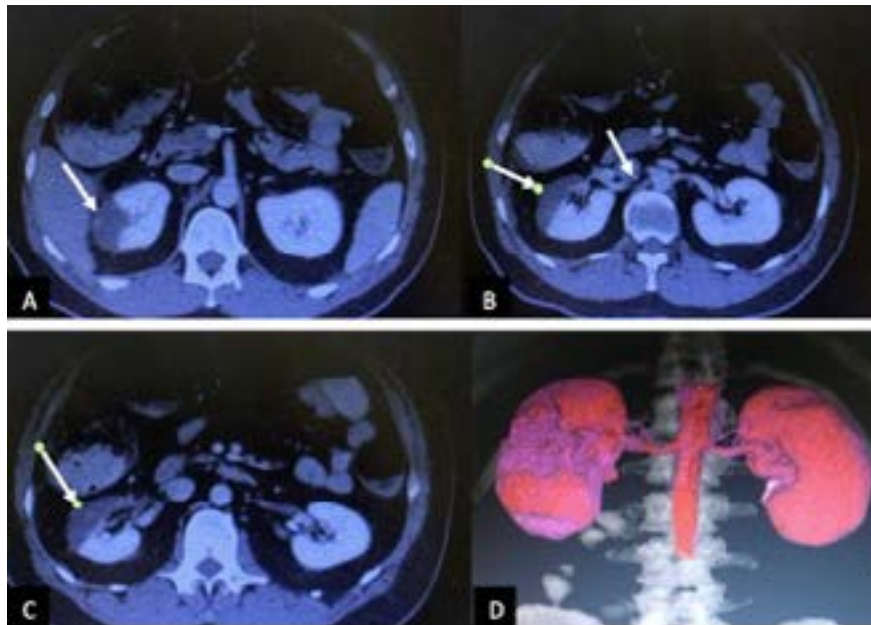
On 08/19, the patient reported abdominal distension with decreased bowel sounds, diffusely painful on deep palpation, not peritoneal. Oral tolerance is suspended, and a nasogastric tube is placed without gagging or vomiting. An abdomen-pelvis CT scan is requested, informing the proximal/middle third of the right renal artery, with images of lack of filling in its interior, and hypodense areas in the right kidney, of triangular morphology with a peripheral base, that are visualized during the contrasted phase consistent with renal infarcts (Fig. 2-3).

Figure 2: Coronal computed tomography image



Coronal computed tomography image (A and B) in the nephrogenic phase showed multiple perfusion defects (arrows) in the right kidney, most pronounced in the upper pole, and lower pole too

Figure 3: Axial abdominopelvic computed tomography image

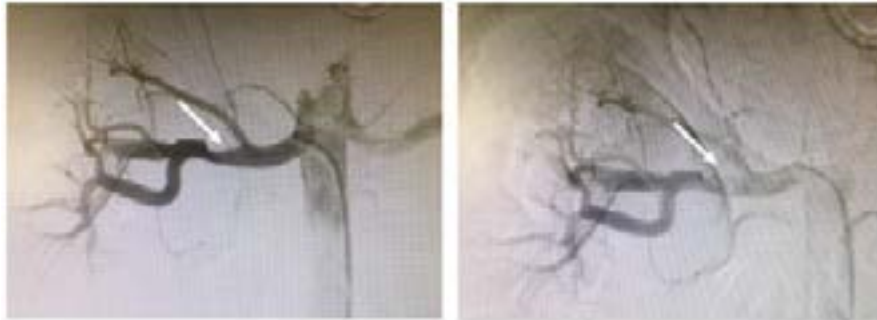

The axial abdominopelvic computed tomography image (A, B and C) revealed perfusion defects (arrows), which sharply demarcated a low attenuation lesion in the right kidney. There is visible thromboembolism in the renal artery (B, arrow). The coronal image (D) showed the areas without perfusion (violet color)

On 08/24, an angiography was performed, with the presence of an ulcerated thrombus in the right renal artery, requiring percutaneous transluminal angioplasty (Fig. 4). It began with double antiplatelet therapy (ASA, acetylsalicylic acid and Clopidogrel) and continued with Enoxaparin.

The patient improved favorably, without distension or abdominal pain, and good oral tolerance with spontaneous ventilation without oxygen requirement (97% saturation).

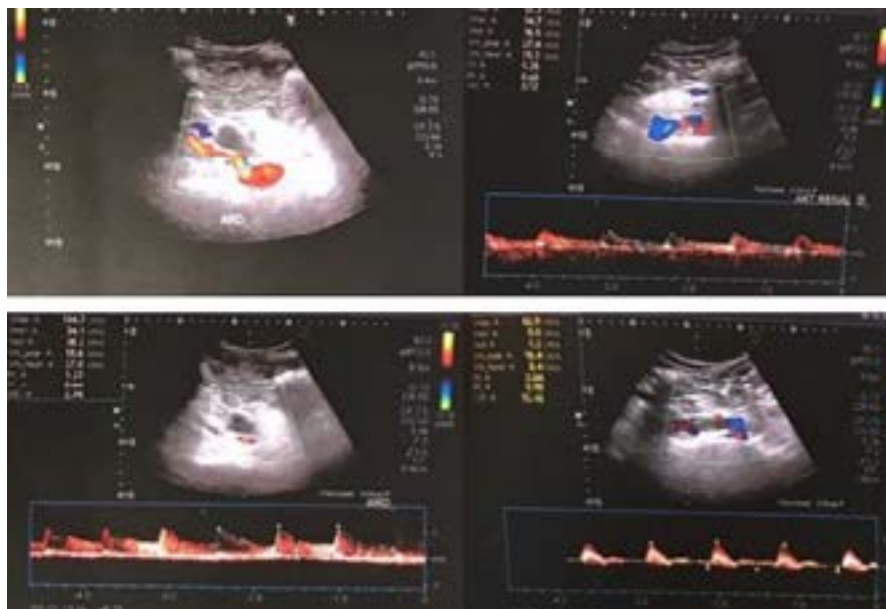
Figure 4: The angiography image



The angiography revealed intramural hematoma of the right kidney artery, with occlusion (arrow). The percutaneous transluminal coronary angioplasty fixed the occlusion and improved the artery irrigation.

Due to clinical improvement, on 08/31 the patient was discharged from the hospital with anticoagulation for 6 months. A recent renal Doppler informed of renal vessels without stenosis. RD with slightly less vascularization and thickness in some cortical areas that appear sequential with respect to the contralateral one (Fig. 5). At present, the patient continues outpatient controls with hematology, cardiology and urology, with good renal function and significant improvement.

Figure 5: The renal Doppler informed of renal vessels without stenosis



The renal Doppler informed of renal vessels without stenosis. The right kidney presented slightly less vascularization and thickness in some cortical areas. The angiography reported an ulcerated thrombus in the right renal artery.

Discussion

The coronavirus disease-2019 (COVID-19) is a viral illness caused by the severe acute respiratory syndrome-coronavirus-2 (SARS-CoV2), and has been deemed a pandemic by the World Health Organization.⁽¹⁾ SARS-CoV-2 is a single-strand RNA coronavirus, which enters human cells mainly by binding the angiotensin-converting enzyme 2 (ACE2), which is highly expressed in lung alveolar cells, cardiac myocytes, the vascular endothelium, and other cell receptors, like those of kidney and intestine.⁽²⁾ Angiotensin-II (AngII) is primarily metabolized by endothelial ACE-2 to the vasodilatory and anti-inflammatory peptide angiotensin. ACE-2 consumption by viral entry would be predicted to increase local AngII concentration. Among the known effects of AngII are vasoconstriction, endothelial activation, and pro-inflammatory cytokine release. Platelet activation by AngII may further enhance a prothrombotic milieu. AngII also has potent chemotactic effects that may accelerate lymphocyte recruitment and suppression.⁽³⁾

SARS-CoV-2 is transmitted primarily after viral particles are inhaled and enter the respiratory tract. In various series, hypertension, smoking, atrial fibrillation, obesity, peripheral vascular disease, previous thromboembolic events, diabetes and estro-progestin therapy are recognized as the main risk factors. Thus, patients with prior cardiovascular disease are at higher risk for adverse events from COVID-19.⁽⁴⁾

Initial symptoms overlap with other viral syndromes, and include fever, fatigue, headache, cough, shortness of breath, diarrhea, headaches, and myalgias. COVID-19 has the potential of resulting in severe illness, including systemic inflammatory response syndrome, acute respira-

tory disease syndrome, multiorgan involvement, and shock. Also, it may predispose hemostatic abnormalities in patients, including disseminated intravascular coagulation or arterial and venous thrombosis, including pulmonary emboli, cerebral infarcts, and limb ischemia. These thrombotic events in COVID-19 patients are higher. So, prophylactic anticoagulation reduces the risk of venous thromboembolism in these patients.⁽⁵⁻⁹⁾

Common laboratory abnormalities include lymphopenia, low levels of platelets and elevation in lactate dehydrogenase (LDH), and inflammatory markers such as C-reactive protein, D-dimer, ferritin, and interleukin-6. COVID-19 appears to induce a hypercoagulable state, with elevated fibrin/fibrinogen, minimal prolongation of prothrombin time, and activated partial thromboplastin time.⁽¹⁰⁻¹²⁾

Recent findings indicate an increased risk of acute kidney injury during COVID-19. The pathophysiological mechanisms which lead to acute kidney injury are not yet fully elucidated, but they may include direct cytopathic effects of the virus on kidney tubular and endothelial cells, indirect damage caused by virus-induced cytokine release, or kidney hypoperfusion due to a restrictive fluid strategy.⁽¹³⁾

The incidence of renal infarction is currently unknown. Renal infarction is usually due to thromboembolism with emboli arising from the heart or aorta in atrial fibrillation, although it can also be caused by other conditions. The clinical presentations are flank pain, nausea, vomiting, hematuria, proteinuria, and/or anuria, and mild fever, which are non-specific. The rarity and non-specific clinical presentation of RI often lead to a delayed diagnosis. Renal angiography is the most sensitive test for diagnosis, but it is not performed on a

routine basis. The improvements in CT technology plays an important role in the diagnosis of renal vascular disease. The laboratory tests performed included urinalysis and standard blood investigations (elevated LDH level). An earlier diagnosis may result in the preservation of renal function in more patients. There is controversy regarding the actual benefit of treatment after prolonged ischemia time.^(14,15)

The treatment includes conservative therapy, such as hydration and blood pressure control, anticoagulation therapy (heparin infusion or a dose of warfarin), and intravascular therapy (thrombolysis and angioplasty). Some studies have reported successful revascularization after prolonged ischemic periods of up to 5 weeks. Several factors may affect the outcome of the treatment, such as ischemia time, collateral flow, and pre-existing kidney disease. The angioplasty is a safe modality of therapy and should be attempted for the purpose of kidney salvage, even in the setting of prolonged ischemia.⁽¹⁶⁾

Conclusions

COVID-19 can cause severe respiratory dysfunction combined with multiple complications including cardiovascular disorders, renal dysfunction, cerebral events and shock. Our patient did not present cardiovascular risk factors and presented the COVID-19 disease with oxygen requirement and renal infarction as a complication. Physicians should consider this problem, and renal artery dissection or renal artery intramural hematoma, in patients with abdominal pain without risk factors, when other intra-abdominal diseases are ruled out. There is currently no specific literature regar-

ding the treatment of these patients. Perhaps, if this case had been treated with early angioplasty, it would have better kidney parenchyma.

Financing:

No sponsorship was received to write this article.

Conflict of interest:

The authors declare no conflicts of interest.

References

1. **Bikdeli B, Madhavan MV, Jimenez D, Chuich T, Dreyfus I, Driggin E, et al.** COVID-19 and Thrombotic or Thromboembolic Disease: Implications for Prevention, Antithrombotic Therapy, and Follow-Up: JACC State-of-the-Art Review. *Journal of the American College of Cardiology*. 2020;75(23):2950–73. doi: 10.1016/j.jacc.2020.04.031
2. **Varga Z, Flammer AJ, Steiger P, Haberecker M, Andermatt R, Zinkernagel AS, et al.** Endothelial cell infection and endotheliitis in COVID-19. *The Lancet*. 2020;395(10234):1417–8. doi: 10.1016/S0140-6736(20)30937-5
3. **Leisman DE, Deutschman CS, Legrand M.** Facing COVID-19 in the ICU: vascular dysfunction, thrombosis, and dysregulated inflammation. *Intensive Care Med*. 2020;46(6):1105–8. doi: 10.1007/s00134-020-06059-6
4. **Cuevas Tascón G, Salazar Chiriboga DE, Lorente Ramos R, Díaz Díaz D, Rodríguez Ruiz C, Procaccini FL, et al.** Infarto renal en paciente con COVID-19. *Nefrología*. 2021;41(1):84–7. doi: 10.1016/j.nefro.2020.04.008

5. **Connell NT, Battinelli EM, Connors JM.** Coagulopathy of COVID-19 and antiphospholipid antibodies. *J Thromb Haemost.* 2020;10.1111/jth.14893. doi: 10.1111/jth.14893
6. **Klok FA, Kruip MJHA, Meer NJM van der, Arbous MS, Gommers D a. MPJ, Kant KM, et al.** Incidence of thrombotic complications in critically ill ICU patients with COVID-19. *Thrombosis Research.* 2020;191:145–7. doi: 10.1016/j.thromres.2020.04.013
7. **Lodigiani C, Iapichino G, Carenzo L, Ceconi M, Ferrazzi P, Sebastian T, et al.** Venous and arterial thromboembolic complications in COVID-19 patients admitted to an academic hospital in Milan, Italy. *Thromb Res.* 2020;191:9–14. doi: 10.1016/j.thromres.2020.04.024
8. **Woehl B, Lawson B, Jambert L, Tousch J, Ghassani A, Hamade A.** 4 Cases of Aortic Thrombosis in Patients With COVID-19. *JACC: Case Reports.* 2020;2(9):1397–401. doi: 10.1016/j.jaccas.2020.06.003
9. **Lushina N, Kuo JS, Shaikh HA.** Pulmonary, Cerebral, and Renal Thromboembolic Disease in a Patient with COVID-19. *Radiology.* 2020;296(3):E181–3. doi: 10.1148/radiol.2020201623
10. **Philipponnet C, Aniort J, Chabrot P, Souweine B, Heng A-E.** Renal artery thrombosis induced by COVID-19. *Clinical Kidney Journal.* 2020;13(4):713. doi: 10.1093/ckj/sfaa141
11. **Griffin DO, Jensen A, Khan M, Chin J, Chin K, Saad J, et al.** Pulmonary Embolism and Increased Levels of d-Dimer in Patients with Coronavirus Disease. *Emerg Infect Dis.* 2020;26(8):1941–3. doi: 10.3201/eid2608.201477
12. **Shi W, Lv J, Lin L.** Coagulopathy in COVID-19: Focus on vascular thrombotic events. *Journal of Molecular and Cellular Cardiology.* 2020;146:32–40. doi: 10.1016/j.yjmcc.2020.07.003
13. **Post A, Deurwaarder ESG den, Bakker SJL, Haas RJ de, Meurs M van, Gansevoort RT, et al.** Kidney Infarction in Patients With COVID-19. *American Journal of Kidney Diseases.* 2020;76(3):431–5. doi: 10.1053/j.ajkd.2020.05.004
14. **Park S, Lee GH, Jin K, Park KM, Kim YW, Park BS.** Renal Infarction Caused by Isolated Spontaneous Renal Artery Intramural Hematoma. *Am J Case Rep.* 2015;16:832–6. doi: 10.12659/AJCR.895285
15. **Hazanov N, Somin M, Attali M, Beilinson N, Thaler M, Mouallem M, et al.** Acute Renal Embolism: Forty-Four Cases of Renal Infarction in Patients With Atrial Fibrillation. *Medicine.* 2004;83(5):292–9. doi: 10.1097/01.md.0000141097.08000.99
16. **Silverberg D, Menes T, Rimon U, Salomon O, Halak M.** Acute renal artery occlusion: Presentation, treatment, and outcome. *Journal of Vascular Surgery.* 2016;64(4):1026–32. doi: 10.1016/j.jvs.2016.04.043