



## Chromosomal and SRY gene findings by FISH in patients with disorders of sexual development

### Hallazgos cromosómicos y del gen SRY por FISH en pacientes con trastornos del desarrollo sexual

Laura Andrea Herrera,<sup>1</sup> Ignacio Zarante,<sup>1</sup> Ana Clavijo,<sup>1</sup> Fernando Suárez,<sup>1</sup>  
 Adriana Rojas,<sup>1</sup> Jaime Pérez,<sup>2</sup> Camila Céspedes,<sup>2</sup> Catalina Forero,<sup>2</sup> Nicolás Fernández,<sup>2</sup>  
 John Bolívar,<sup>2</sup> Olga Moreno-Niño.<sup>1</sup>

#### Abstract

**Objective:** Disorders of sexual development are a group of congenital diseases that affect the normal formation of genital structures. Within the pathophysiologic mechanisms described, there are genetic factors caused by chromosomal or sex-determining gene alterations. Therefore, chromosomal analysis is an essential priority in the diagnostic approach. Alterations in the chromosomes and the SRY gene as a cause of disorder of sexual development was analyzed herein.

**Material and methods:** G or R-banding karyotype and FISH analyses for the SRY gene were performed in lymphocytes, gonadal tissue, and scrotal tissue in twelve cases, three cases, and one case, respectively. The clinical information was obtained from the patients' medical reports.

**Results:** In 9 (73%) cases, the assigned sex was male, and in 3 (27%) cases, it was female. Karyotype 46,XY was found in 8 (66%) cases, 46,XX in 2 (17%) cases, and mosaic karyotype in 2 (17%) cases with idic(Y). A single case of gonadal tissue showed mosaicism due to the presence of a tetraploid cell line. The most common clinical diagnosis was abnormal genital differentiation in 8 (67%) cases, followed by hypospadias in 5 (41.7%) cases.

**Conclusions:** The results show the importance of applying different cytogenetic tests in making the diagnosis, and the need for a multidisciplinary team to address the disorder.

#### Keywords:

Disorders of sexual development, Karyotype, FISH, SRY gene, chromosomal mosaicism, Isodicentric Y chromosome

#### Corresponding author:

\* Olga Moreno-Niño  
Dirección: Instituto de Genética Humana, Facultad de Medicina, Pontificia Universidad Javeriana; Cra 7 #40-62, edificio 32, 110231. Bogotá-Colombia. Correo electrónico: moreno-o@javeriana.edu.co

**Citation:** Herrera L., Zarante I., Clavijo A., Suárez F., Rojas A., Pérez J., et al. *Chromosomal and SRY gene findings by FISH in patients with disorders of sexual development. Rev Mex Urol.* 2021;81(3):pp. 1-12

<sup>1</sup> Pontificia Universidad Javeriana, Bogotá, Colombia.

<sup>2</sup> Hospital Universitario San Ignacio, Bogotá, Colombia.

**Received:** September 30, 2020

**Accepted:** May 15, 2021



## Resumen

**Objetivo:** Los trastornos del desarrollo sexual son un grupo de enfermedades congénitas que afectan la formación normal de los genitales. Dentro los mecanismos fisiopatológicos descritos existen factores genéticos causados por alteraciones cromosómicas o en los genes determinantes en la diferenciación sexual. En este trabajo se analizaron alteraciones cromosómicas y en el gen SRY como posible causa del trastorno. Se realizó cariotipo con bandas G o R y FISH para SRY en linfocitos, tejido gonadal y tejido escrotal.

**Materiales y métodos:** La información clínica de los sujetos de investigación se obtuvo de los informes de los médicos tratantes. En 9 (73%) casos el sexo asignado fue masculino y en 3 (27%) casos fue femenino. 8 de los casos (66%) tuvieron cariotipo 46,XY; 2 casos (17%) 46,XX y en 2 casos (17%) se reportaron mosaicos con presencia de idic(Y). Un solo caso de tejido gonadal mostró mosaicismo debido a la presencia de una línea celular tetraploide. El diagnóstico clínico más frecuente fue de genitales ambiguos en 8 casos (67%). Seguimiento de hipospadias en 5 casos (41,7%).

**Conclusiones:** Los resultados muestran la importancia de aplicar diferentes pruebas citogenéticas en el diagnóstico y la necesidad del seguimiento de los pacientes por un equipo transdisciplinario para abordar estas condiciones clínicas.

### Palabras clave:

Trastornos del desarrollo sexual, cariotipo, FISH, gen SRY, Mosaico cromosómico, cromosoma Y isocéntrico.

## Introduction

Disorders of sexual development involve congenital alterations related to the formation of sexual characteristics.<sup>(1)</sup> Those abnormalities are caused by a mismatch between chromosomal, gonadal, and phenotypic sex, thus requiring multidisciplinary management for proper diagnosis, treatment, and follow-up.<sup>(1-3)</sup> Disorders of sexual development include a broad spectrum of phenotypes, and their prevalence is not clearly determined. DSD is estimated to account for approximately 7.5% of all birth defects, worldwide.<sup>(4)</sup> A prevalence of DSD of 0.76 per 4,500 births has been reported in Colombia.<sup>(5)</sup>

The correct determination of dysmorphic sex and the achievement of that differentiation can be interrupted by genetic and/or non-genetic factors, capable of altering any of the molecular signals that define the specific sexual development of the sex organs or endocrine function.<sup>(3)</sup> Most of those phenotypic alterations are very complex to diagnose and difficult to treat, so they must be approached by a multidisciplinary team, with the appropriate experience and knowledge for managing those conditions.<sup>(6-8)</sup>

Human sex determination involves the differentiation of the originally dimorphic embryo into an individual with distinct male or female reproductive roles. That process can be interrupted by genetic and/or non-genetic factors capable of altering any of the molecular signals that specify the specific sexual development of the sexual organs or endocrine function.

Chromosomal alterations, particularly of the sex chromosomes, or alterations in genes involved in early sex determination, such as the SRY gene, are genetic mechanisms associated with the development of disorders of sexual development (DSD).<sup>(9,10)</sup> The 2006 Chicago Consensus on management of DSD introduced a new classification based on karyotype. That classification includes sex chromosomes DSD, 46,XY DSD, and 46,XX DSD. Therefore, chromosomal analysis is important in identifying the underlying cause of the disorder, and is considered a priority in making the diagnosis, as well as in directing patient management.<sup>(2)</sup> Due to the difficulties in the complete cytogenetic diagnosis of many patients with DSD and inconclusive results in their tests, the aim of our work was to determine the presence of chromosome and SRY gene alterations, in patients clinically diagnosed with DSD, to support the diagnosis. We analyzed 12 patients with different clinical conditions of DSD, to establish their chromosomal condition and the presence or absence of the SRY gene, as a cause of the disorder. Of that group of individuals, 8 (66%) were classified as DSD 46,XY, 2 (17%) as DSD 46,XX, and 2 (17%) as DSD due to mosaic chromosomal abnormalities. Our results demonstrate the importance of performing cytogenetic tests as the initial diagnostic approach for this type of clinical condition, enabling a first approximation of the genetic panorama

involved in the etiology of the disorder and aiding in the decision-making, with respect to the monitoring of the patient.

## Methodology

Twelve patients diagnosed with DSD from the departments of urology or genetics were evaluated during 2014. All patients included in the study were diagnosed with DSD, with suspected alteration in the sex chromosomes and/or the SRY gene, as a possible cause of the pathology. Patients with DSD whose phenotype was caused by hormonal disorders or with known syndromes, such as Turner syndrome or Klinefelter syndrome, were excluded. In all cases, the patient and his/her parent or guardian received information about the study and signed the consent form to carry out the cytogenetic tests and access the patient's medical history. The protocol was approved by the Ethics Committee of the School of Medicine of the *Pontificia Universidad Javeriana* and the *Hospital Universitario San Ignacio*.

Blood samples were collected from all patients in a tube with heparin and a cell culture was performed for high resolution karyotyping in RPMI 1640 (Sigma), supplemented with 10% fetal bovine serum (FBS) (Eurobio) and phytohemagglutinin (Gibco) as a mitogen. Cellular synchronization was performed with a final concentration of methotrexate [10-7M] (Sigma) and unblocking was carried out with a final concentration of thymidine [1x10-5M] or BrdU [30µg/ml] (Sigma), to obtain metaphase chromosomes. High-resolution G (BG) (HCl-Wright) or R (BR) (Hoechst-Giemsa) banding was obtained through staining, according to a standardized laboratory protocol.<sup>(11)</sup>

Karyotype analysis was performed in gonadal or fibroblast tissue in three cases, in which a biopsy was performed for pathologic studies, and a small section of that biopsy tissue was used for cell culture and karyotype analysis. The tissue was cut into small fragments that were placed in a culture flask with RPMI and 20% SFB for fibroblast-like cell growth, mono-layer confluence, and finally in-situ cell growth on a plate, to obtain metaphase chromosomes. In each case, 50 metaphases from lymphocytes with 550 to 700 band resolution were evaluated, whereas in solid tissues, the resolution level was 300 to 450 bands; in cases with mosaicism and sufficient material for evaluation, reading was extended to 100 metaphases. Fluorescence in situ hybridization (FISH) was performed with a specific probe for the SRY gene (SRY Probe, Cytocell Aquarius) and a centromere (DYZ3 a-satellite Probe, Cytocell Aquarius) for the Y chromosome, through standard protocol indicated by the supplier. The results were

reported using the International System for Human Cytogenetic Nomenclature.<sup>(12)</sup> In all cases, a geneticist and/or the multidisciplinary DSD group of the *Hospital Universitario de San Ignacio* clinically assessed the participant to obtain the clinical data.

## Results

Table 1 shows the data on age, assigned sex, and clinical characteristics of the group of patients analyzed. The average age was 7 years, ranging from 2 months to 44 years. In 9 (73%) cases, the sex assigned at birth was male, and in 3 (27%) cases it was female. The most frequent clinical finding was abnormal genital differentiation in 8 cases (67%). Other relevant findings in our series were 9 (75%) cases of micropenis and 5 (41.6%) cases of hypospadias, as shown in Table 1.

**Table 1. Clinical characteristics of the cases assessed and results of the karyotype and FISH analyses**

Case No.	Age	Assigned Sex	Clinical Characteristics	Karyotyping and FISH Results
1*	2 Years	M	Ambiguous genitalia, Ovotestis. 3 cm long genital tubercle. Urogenital sinus at the base of the tubercle.	In blood 46,XX.ish Yp11.31(SRY-)  In gonads mos 92,XXXX[12]/46,XX[38].ish Yp11.31(SRY-)
2	8 Mon.	M	Ambiguous genitalia. Bifid scrotum, hypospadias, and micropenis.	46,XY.ish Yp11.31(SRY+)

Continúa...

Case No.	Age	Assigned Sex	Clinical Characteristics	Karyotyping and FISH Results
3*	3 Years	M	Ovotestis. Phallus approx. 2 cm with severe hypospadias. Left movable mass at the labioscrotal folds, hypopigmented, redundant skin, opened glans, and proximal retraction. Psychomotor development disorder, short height.	In blood mos 45,X[4]/46,XY[96]. ish idic(Y) (SRY++,DYZ3++,DYZ1-)  In scrotal skin mos 45,X[97]/46,XY[3].ish idic(Y) (SRY++,DYZ3++,DYZ1-)
4	4 Years	F	Ambiguous genitalia, 2.5 cm long genital tubercle with major fusion of the labioscrotal folds, no structure showing verumontanum remains and/or vagina, ovary in the right gonad. RG: Ovary. LG: Ovotestis.	46,XX.ish Yp11.31 (SRY-)
5	4 Mon.	M	Ambiguous genitalia. Phallus approx. 1.5 cm and inguinoscrotal folds, nonpalpable gonads.	46,XY.ish Yp11.31(SRY+)
6	2 Years	M	Hypospadias	46,XY.ish Yp11.31 (SRY+)
7	2 Years	M	Severe proximal hypospadias	46,XY.ish Yp11.31(SRY+)
8*	44 Years	F	Hypoplastic uterus with 22 cc volume and proper vagina differentiation. No gonadal tissue was identified. Physical examination revealed healthy, non-atrophic female external genitalia, normal pubic hair; speculscopy: short healthy vagina, regular small uterus.	46,XY.ish Yp11.31 (SRY+)
9	13 Years	M	Ambiguous genitalia. Aphallia, presence of two labioscrotal folds suggestive of scrotum with no lumen, unidentifiable right gonad, empty left labioscrotal fold.	46,XY.ish Yp11.31(SRY+)
10*	2 Years	F	Ambiguous genitalia. 2 cm long genital tubercle with clitoromegaly. Hypoplastic uterine tube and 3 cm uterus, with no ovaries. Cardiac abnormality.	mos 45,X[19]/46,XY[23]/47,XYY[8].ish idic(Y)(SRY++,DYZ3++,DYZ1-) /idic(Y) (SRY++,DYZ3++,DYZ1-)x2

Continúa...

Case No	Age	Assigned Sex	Clinical Characteristics	Karyotyping and FISH Results
11	2 Mon.	M	Ambiguous genitalia. Phallus with pointed-shaped urethral orifice, testes, normally pigmented rough scrotal sacs.	46,XY.ish Yp11.31(SRY+)
12	3 Years	M	Ambiguous genitalia. 1 cm long genital tubercle. Anus-urogenital sinus distance 6.5 cm, hypoplastic scrotum, urethral meatus orifice at the base of the genital tubercle, palpable gonads at bilateral inguinal canal level, hypoplastic inguinoscrotal folds with mild pigmentation, penoscrotal hypospadias, testes in scrotum, Tanner 2. Short height.	In blood and gonads 46,XY.ish Yp11.31(SRY+)

Mon.: Months, M: male, F: female, RG: right gonad, LG: left gonad

\* These patients were included in García-Acero et al. (23) as part of the recorded medical histories of the patients with chromosomal alterations, analyzed at our institution.

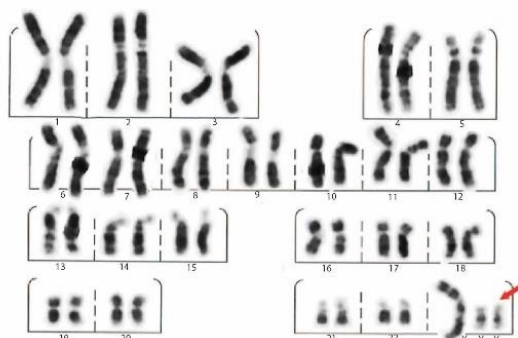
In 9 cases (75%), with information on the status of the internal sexual organs, 5 (45%) of them had undefined or unidentifiable gonads, 3 (18%) had ovotesticular tissue, and 1 (9%) had normal gonads. The main reasons for consultation were unilateral or bilateral cryptorchidism, in 5 cases (41.6%); hypospadias, 5 cases (41.6%); and primary amenorrhea, 1 case (8.3%). Among the associated characteristics, alterations, such as aphallia, bifid/hypoplastic scrotum, clitoromegaly, and psychomotor development disorders, were reported.

Among the important antecedents found in 5 (33.4%) cases were: threatened abortion, use of intravaginal ovules during pregnancy, use of hormonal therapy (levonorgestrel, estrogens) during pregnancy without medical indication, and history of renal congenital anomaly in second degree of consanguinity. In 7 (58%) cases, the personal background could not be clearly established.

Table 1 shows the results of the cytogenetic analyses. In the blood cell analysis of the 12 individuals, 8 (66%) had 46,XY karyotype, 2 (17%) 46,XX karyotype, and 2 (17%) mosaic karyotype (Table 1). In 2 (33.3%) cases (1 and 8) there was no coincidence in the result of the karyotype and FISH analyses with the assigned sex: one with karyotype 46,XX and absence of SRY (SRY-), and the other with karyotype 46,XY and presence of SRY (SRY+); and they were assigned a male and female phenotype, respectively (Table 1). Both cases with mosaic karyotype (cases 3 and 10) occurred due to alteration in the sex chromosomes. Both cases presented a cell line with the absence of a sex chromosome (45,X), and at least a second line with the presence of a Y chromosome (Figure 1).

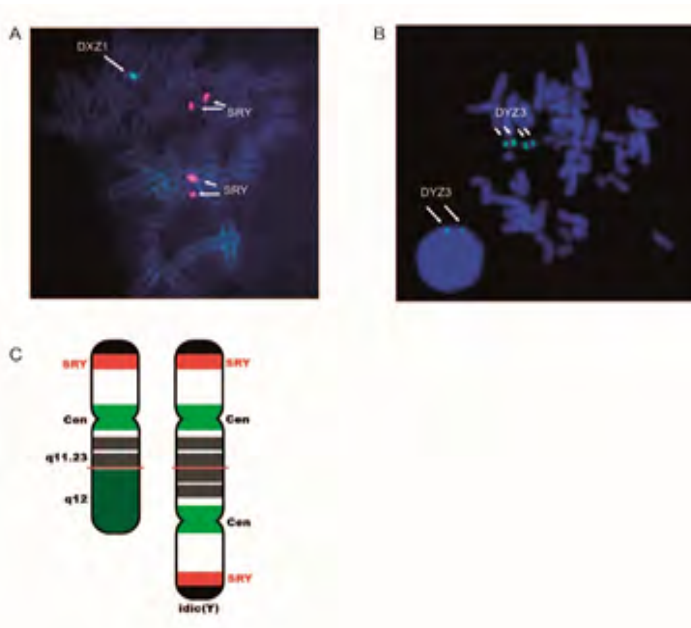
Figure 1. Karyotype 47,XYY of the cell line with two Y chromosomes in case 10. Y chromosomes (arrow) with normal appearance in the R-banding karyotype analysis

Figure 1



In both cases, the FISH test detected a signal from the SRY gene at each end (SRY++) of the Y chromosomes, and absence of the heterochromatin region in Yq12 (DYZ1-) (Figure 2A). The probe for the centromeric region showed two centromeres on the Y chromosome, revealing isodicentric chromosomes (DYZ3++) in both cases (Figure 2B and 2C). The sex assigned at birth in those patients was male (case 3) and female (case 10) (Table 1). Gonad karyotype and FISH analyses of cases 1 and 12 coincided with the chromosomal constitution of the blood karyotype. However, in case 1, a second tetraploid cell line was observed in both gonads (Table 1). In case 3, the karyotype analyses performed on the cells taken from the scrotal tissue biopsy confirmed the presence of mosaicism, inversely proportional to that found in blood (Table 1).

Figure 2. Result of FISH analysis in blood for case 10, with female phenotype and abnormal genital differentiation



A. FISH image in metaphase 47,XYY; the two isodicentric Y chromosomes can be seen, with the presence of two SRY signals (red) in each and the absence of the Yq12 region (green); the aquamarine signal corresponds to DXZ1 for the chromosome X centromere. 47,XYY.ish idic(Y)(q11.2)(DYZ1-,SRY++)x2.  
 B. FISH image with DYZ3 centromeric probe in metaphase, where two Y chromosomes with double centromere (green) 47,XYY can be seen, as well as two centromeric signals in the nucleus on a single Y chromosome, cell line 46,XY. 47,XYY.ish idic(Y)(q11.2)(DYZ3++)x2  
 C. Ideogram of the isodicentric Y chromosome. Probes used SRY probe Cytocell Aquarius and DYZ3 alpha-satellite Probe, Cytocell Aquarius.

## Discussion

DSD are a group of conditions that include one or more of the following cases: congenital development of abnormal genital differentiation, congenital discordance between internal and external sexual anatomy, alterations of sex chromosomes, and disorders of gonadal development.<sup>(1,3,13)</sup> We analyzed herein 12 patients with different clinical conditions included in DSD, to establish their chromosomal condition and the presence or absence of the SRY gene, as a cause of the disorder. Of that group of individuals, 8 (66%) were classified as DSD 46,XY, 2 (17%) as DSD 46,XX, and 2 (17%) as DSD due to mosaic chromosomal abnormalities. The prevalence of those disorders is not well known but some studies report a higher frequency of DSD-XY individuals, followed by DSD-XX individuals, and finally DSD due to chromosomal abnormalities.<sup>(2)</sup> Because the group of cases analyzed was so small, it was not

possible to establish the prevalence of each of those conditions. However, 66% of our cases were DSD-XY, which is consistent with the percentages reported.

DSD 46,XY individuals are characterized by having a chromosomally masculine karyotype with no alterations, with phenotypes that can range from mild hypospadias to completely female internal and external genitalia.<sup>(14)</sup> That phenotype has been associated with mutations, deletions, duplications, or alterations in the regulation of genes responsible for the determination of sex development and hormonal function, such as SRY, NR0B1, SOX9, NR5A1, DAX1, LHR, and AR/NR3C4, among many others.<sup>(9,10,15)</sup> From a clinical perspective, the 8 DSD 46,XY cases described herein showed conditions including hypospadias with different degrees of severity, sexual ambiguity, and a case of completely female phenotype. The SRY gene was physically present in all cases, indicating no loss, and therefore may not be involved in the presentation of DSD in those patients. However, the presence of mutations in the gene cannot be ruled out, so it cannot be definitively eliminated as a cause of the disorder, especially in the case with a female phenotype. The SRY gene encodes a transcription factor (SRY protein), whose main function is to induce the gene activation cascade that directs the development of the testis from an undifferentiated bipotential gonad.<sup>(16,17)</sup> That gene is located in the short arm of the Y chromosome (Yp11.3), and the presence of protein-inactivating mutations has been associated with gonadal dysgenesis 46,XY.<sup>(17)</sup>

The two 46,XX cases had abnormal genital differentiation and ovotestis, absence of the SRY gene, and male and female phenotype, respectively. Although individuals with male



sex reversal are generally uncommon in 46,XX DSD, that phenotype has been linked to the presence of the SRY gene due to translocation to the X chromosome during meiosis. However, in our two cases, the gene was not detected by FISH in blood or the gonadal cells. The presence of polyploid lines in gonadal tissue, as in case 1, which could have a dose effect and influence sex determination, has not been reported, so further studies are required to confirm their effect. Alterations in the function of genes, such as NR5A1, SOX3, WNT4, and RSPO1, have been related to ovotesticular DSD in the absence of SRY,<sup>(10)</sup> and should be investigated in such cases.<sup>(9)</sup>

In DSD due to chromosomal abnormalities, it is rare to find 45X/46,XY and 45,X/47,XYY mosaicism, and it presents an approximate incidence of 1.7/10,000 pregnancies.<sup>(18)</sup> It has been estimated that only 5%-10% of individuals with those anomalies have abnormal genital differentiation at birth, and the rest have a male phenotype.<sup>(19)</sup> Cases with mosaicism can vary from male phenotypes with cryptorchidism or hypospadias to female phenotypes with gonadal dysgenesis. The typical combination in those patients is asymmetry in testis development on one side, and gonadal striae with persistence of Müllerian derivatives on the opposite side.<sup>(18)</sup> The first of our two cases with mosaicism (case 3), assigned male phenotype and karyotype mos 45,X/46,X,idic(Y)(q11.2), concurred with those typical characteristics. In the second case, with assigned female phenotype, and whose mosaicism included the presence of a third cell line with two isodicentric Y chromosomes, no information on her gonadal status was obtained. In the latter case, the presence of clitoromegaly, cardiac abnormality, and assigned female phenotype

suggested Turner syndrome phenotype in the patient and was not reported at the time of this study. Phenotypes associated with Turner syndrome may be present in those patients, so monitoring the clinical signs of said syndrome is recommended.<sup>(9)</sup> Furthermore, the risk of gonadal germ cell tumors (gonadoblastoma) due to the presence of the Y chromosome or of Y-derived sequences should be monitored.<sup>(20,21)</sup> On the other hand, it has been suggested that duplication of the SRY gene in cases with 45,X/46,X,idic(Yp) mosaicism does not determine male or female sex differentiation, but that it possibly depends on the proportion of each cell line in gonadal tissue.<sup>(22)</sup> In our two cases, each one with a different assigned sex, the cell line distribution in the gonadal tissue was impossible to confirm; in the first case, gonadal tissue was not available for analysis, and the second case was lost to follow-up.

Clinically, DSD are very complex and difficult to diagnose and treat.<sup>(6-8)</sup> In addition to that complexity, the patient's family environment is also strongly affected and has an effect on adequate management. Therefore, for comprehensive management, a timely approach by a multidisciplinary team with experience in DSD is recommended. Such a team should include neonatologists, endocrinologists, urologists/surgeons, gynecologists, geneticists, obstetricians, radiologists, pediatric nurse educators, andrologists, psychologists, and psychiatrists, among other specialists involved in the care of infants, children, adolescents, and adults with DSDs.<sup>(8,10)</sup> Our group of patients was treated by a multidisciplinary team.

The greatest difficulty was related to the healthcare system, specifically in directing patients for comprehensive management, and in some cases, it affected their treatment,

follow-up, and family counseling. Such inconveniences are frequent in our healthcare system, especially in relation to highly complex disorders, such as DSD.<sup>(8)</sup> In that context, and according to our experience, as well as that of various groups working with DSD around the world, the presence of abnormal genital differentiation in a newborn must be treated as a medical emergency. A multidisciplinary clinical evaluation should be carried out, to establish a diagnosis and adequate sex assignment to the newborn.<sup>(8)</sup> Likewise, when DSD is detected before birth by conflicting prenatal karyotype and ultrasound imaging results, the multidisciplinary team must intervene to confirm the diagnosis immediately at birth. DSD can also appear during childhood, associated with other syndromic characteristics; during adolescence due to virilization, absence of puberty, or primary amenorrhea; and during adulthood, associated with infertility, gonadal tumors, and other complications.<sup>(6,9,23)</sup> Regardless of the specific needs of each of those groups, a timely multidisciplinary team intervention is always recommended.

The results presented herein show us the importance of cytogenetic analyses in the diagnosis of DSD. They are essential for making decisions in the treatment and monitoring of the patient and for counseling the individual and/or family. It is clear that those results, together with the clinical analysis of the patients, contribute to the diagnosis and/or classification of the disorder. In addition, in cases such as those with hypospadias and no cytogenetic alteration, the results can be relevant for continuing to search for the etiology of the disorder. Likewise, we consider that cytogenetic studies in gonadal tissue, in addition to the histopathologic study, can be of great help in discerning the origin of

the pathology. Importantly, in our cases with mosaicism, the Y chromosomes had a relatively normal appearance in the karyotype, and the isodicentric structure was detected only after the FISH test was applied, reinforcing the importance of using different cytogenetic methodologies to determine the genetic etiology of DSD. Methods, such as MLPA and CGH-microarray, could be useful in the search for copy number variations (CNVs) in the sex determination genes, whereas the complete genome analysis could be useful in detecting mutations or new genes involved in those processes.<sup>(9,15)</sup> Because environment has been proposed to play a large role in the etiology of the disorder, epigenetic analysis of the genes regulated by that mechanism would greatly help to understand those clinical conditions.

## Conclusion

Cytogenetic results allowed us to establish the cause of the phenotype in two cases, and they suggested that other genes or regulatory mechanisms were involved in two other cases. The results show the importance of applying different cytogenetic tests in the diagnosis of DSD, and the need for a multidisciplinary team to assess the patient and direct the treatment, follow-up, and counseling. The present study paves the way for the corroboration with other molecular studies of the SRY gene or other genes or mechanisms regulating sexual organ development, because in all cases, there were clinical alterations associated with DSD. Furthermore, the commitment of the healthcare authorities to their communities is extremely important, to reduce the risk of disability in those affected.

## Conflict of interest

The authors declare there are no potential conflicts of interest, with respect to the research, authorship, and/or publication of this article.

## Funding

This work was funded by resources of the *Instituto de Genética Humana*, ID PPTA 0000585, and *Hospital Universitario San Ignacio*.

## Acknowledgment

We wish to thank the patients that participated in this study, the *Hospital Universitario San Ignacio*, and the different hospitals in Bogotá that referred the patients. We also wish to thank the geneticist, Ana María Zarante MD, and Jorge Rojas MD, who referred some of the patients, as well as the residents of the Clinical Genetics specialty, for treating the patients.

## References

1. **García-Acero M, Moreno O, Suárez F, Rojas A.** Disorders of Sexual Development: Current Status and Progress in the Diagnostic Approach. *CUR*. 2019;13(4):169–78. doi: 10.1159/000499274
2. **Hughes IA.** Disorders of sex development: a new definition and classification. *Best Pract Res Clin Endocrinol Metab*. 2008;22(1):119–34. doi: 10.1016/j.beem.2007.11.001
3. **Achermann J, Hughes IA.** Sexual Dysfunction in Men and Women. In: *Williams Textbook of Endocrinology*. 13th ed. 2016. p. 785–830.
4. **Eid W, Biason-Lauber A.** Why boys will be boys and girls will be girls: Human sex development and its defects. *Birth Defects Research Part C: Embryo Today: Reviews*. 2016;108(4):365–79. doi: <https://doi.org/10.1002/bdrc.21143>
5. **Zarante I, Franco L, López C, Fernández N.** Frequencies of congenital malformations: assessment and prognosis of 52,744 births in three cities of Colombia. *Biomédica*. 2010;30(1):65–71. doi: 10.7705/biomedica.v30i1.154
6. **Brain CE, Creighton SM, Mushtaq I, Carmichael PA, Barnicoat A, Honour JW, et al.** Holistic management of DSD. *Best Pract Res Clin Endocrinol Metab*. 2010;24(2):335–54. doi: 10.1016/j.beem.2010.01.006
7. **Mouriquand PDE, Gorduza DB, Gay C-L, Meyer-Bahlburg HFL, Baker L, Baskin LS, et al.** Surgery in disorders of sex development (DSD) with a gender issue: If (why), when, and how? *J Pediatr Urol*. 2016;12(3):139–49. doi: 10.1016/j.jpuro.2016.04.001
8. **Fernandez N, Moreno O, Rojas A, Céspedes C, Forero C, Mora L, et al.** Manejo transdisciplinario de pacientes con desórdenes del desarrollo sexual en Colombia. Limitantes para un manejo oportuno e integral. *Urología Colombiana*. 2017;26(3):164–8. doi: 10.1016/j.uroco.2016.06.004
9. **Achermann JC, Domenice S, Bacheega TASS, Nishi MY, Mendonca BB.** Disorders of sex development: effect of molecular diagnostics. *Nat Rev Endocrinol*. 2015;11(8):478–88. doi: 10.1038/nrendo.2015.69
10. **Witchel SF.** Disorders of sex development. *Best Pract Res Clin Obstet Gynaecol*. 2018;48:90–102. doi: 10.1016/j.bpobgyn.2017.11.005
11. **Clouston H.** Lymphocyte culture. In: *Human Cytogenetics constitutional analyses*. 3rd ed. London: Rooney DE Editor; 2001.
12. **McGowan-Jordan J, Simons A, Schmid M, Karger S.** *ISCN 2016 | Karger Book*. 2016.

- [accessed 3 Jun 2021] Available from: <https://www.karger.com/Book/Home/271658>
13. **Olshan J, Eimicke T, Belfort E.** Gender Incongruity in Children With and Without Disorders of Sexual Differentiation. *Endocrinol Metab Clin North Am.* 2016;45(2):463–82. doi: 10.1016/j.ecl.2016.02.001
  14. **Rodríguez-Buritica D.** Overview of genetics of disorders of sexual development. *Curr Opin Pediatr.* 2015;27(6):675–84. doi: 10.1097/MOP.0000000000000275
  15. **García-Acero M, Molina M, Moreno O, Ramirez A, Forero C, Céspedes C, et al.** Gene dosage of DAX-1, determining in sexual differentiation: duplication of DAX-1 in two sisters with gonadal dysgenesis. *Mol Biol Rep.* 2019;46(3):2971–8. doi: 10.1007/s11033-019-04758-y
  16. **Kashimada K, Koopman P.** Sry: the master switch in mammalian sex determination. *Development.* 2010;137(23):3921–30. doi: 10.1242/dev.048983
  17. **McClelland K, Bowles J, Koopman P.** Male sex determination: insights into molecular mechanisms. *Asian J Androl.* 2012;14(1):164–71. doi: 10.1038/aja.2011.169
  18. **Farrugia MK, Sebire NJ, Achermann JC, Eisawi A, Duffy PG, Mushtaq I.** Clinical and gonadal features and early surgical management of 45,X/46,XY and 45,X/47,XYY chromosomal mosaicism presenting with genital anomalies. *J Pediatr Urol.* 2013;9(2):139–44. doi: 10.1016/j.jpuro.2011.12.012
  19. **Chang HJ, Clark RD, Bachman H.** The phenotype of 45,X/46,XY mosaicism: an analysis of 92 prenatally diagnosed cases. *Am J Hum Genet.* 1990;46(1):156–67.
  20. **Abacı A, Çatlı G, Berberoğlu M.** Gonadal malignancy risk and prophylactic gonadectomy in disorders of sexual development. *J Pediatr Endocrinol Metab.* 2015;28(9–10):1019–27. doi: 10.1515/jpem-2014-0522
  21. **Huang H, Wang C, Tian Q.** Gonadal tumour risk in 292 phenotypic female patients with disorders of sex development containing Y chromosome or Y-derived sequence. *Clin Endocrinol (Oxf).* 2017;86(4):621–7. doi: 10.1111/cen.13255
  22. **Guedes AD, Bianco B, Lipay MVN, Brunoni D, Chauffaille M de L, Verreschi ITN.** Determination of the sexual phenotype in a child with 45,X/46,X,Idic(Yp) mosaicism: Importance of the relative proportion of the 45,X line in gonadal tissue. *American Journal of Medical Genetics Part A.* 2006;140A(17):1871–5. doi: <https://doi.org/10.1002/ajmg.a.31363>
  23. **Acero MG, Moreno O, Gutiérrez A, Sánchez C, Cataño JG, Suárez-Obando F, et al.** Novel homozygous mutation in a colombian patient with persistent müllerian duct syndrome: expanded phenotype. *Int Braz J Urol.* 2019;45(5):1064–70. doi: 10.1590/S1677-5538.IBJU.2018.0808