



Atypical metastases from a renal tumor

David Hernández-Alcaraz,^{1*} Begoña Beneto-Alducin,¹ Pedro Morales-Jiménez,¹

Abstract

Background: The aim of the present work was to present three clinical cases with uncommon presentations of metastatic kidney cancer.

Clinical cases: The first case was that of a woman that presented with metastasis to the thyroid gland after thyroidectomy. The rest of the extension studies were negative, and she did not require adjuvant treatment. The second case was a woman that came to the emergency department due to urinary retention secondary to urethral metastasis from a kidney tumor, with no metastases at other levels. The third case was a man that presented with recurrence of papillary renal cell carcinoma in the bladder mucosa associated with lung metastases.

Discussion: Thirty-four percent of metastases to the thyroid gland have a renal origin. The urethra is an uncommon site for metastasis. In general, bladder metastases from renal carcinoma have a poor prognosis, with only 56 cases described in the literature. The treatment of choice for resectable lesions is surgical extirpation, and anti-angiogenic therapy is reserved for nonresectable lesions.

Conclusions: The thyroid gland, bladder, and urethra are uncommon sites of metastases from kidney cancer. They tend to indicate advanced disease stages and treatment is surgical extirpation in cases of resectable lesions.

Keywords: Kidney tumor, Metastasis, Treatment.

Reference: Hernández-Alcaraz, D. Beneto-Alducin B., Morales-Jiménez P., Atypical metastases from a renal tumor. Rev. Mex. Urol. 2019;79(1):pp.1-7

Corresponding author:

* David Hernández-Alcaraz, Hospital Regional Universitario de Málaga. Av. de Carlos Haya, 84, 29010 Málaga, Spain
Email: davidhauro@hotmail.com

¹ Servicio de Urología. Hospital Regional Universitario de Málaga, Spain.

Received: February 27, 2018

Accepted: December 13, 2018



Introduction

Kidney tumors account for approximately 3% of the cancers that affect humans and their incidence is believed to increase slightly each year. Half of kidney tumors are asymptomatic and one-third of patients with symptoms present with metastatic disease. In addition, one-fourth of patients with kidney cancer have metastasis at diagnosis⁽¹⁾ and one-third of patients with disease confined to the kidney present with local or distant metastasis after treatment.⁽²⁾

The classic sites of metastasis from kidney tumors are the lungs (50%), bone (49%), lymph nodes (6-32%), skin (11%), liver (8%), and brain (3%).⁽³⁾ The majority of metastases occur after the first 5 years, especially at the first 3 sites mentioned.

The aim of the present work was to present three clinical cases of renal carcinoma with uncommon sites of metastases.

Case presentation

Case 1: A 61-year-old woman had an unremarkable past medical history. She came to the endocrinology service for consultation due to a nodule in the right thyroid lobe, with no associated symptomatology. Fine needle aspiration (FNA) revealed atypical cells and thyroidectomy was performed due to the diagnostic suspicion of papillary thyroid carcinoma. Anatomopathologic study of the specimen showed 4 nodules with clear cell carcinoma that affected both thyroid lobes and the thyroid capsule. Probable kidney metastasis was diagnosed (figures 1 and 2).

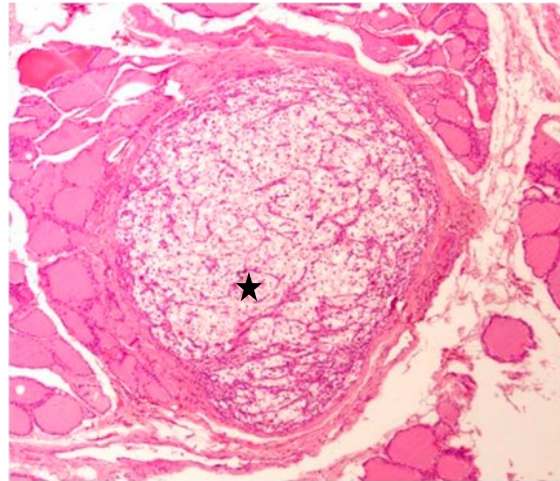


Figure 1 Hematoxylin and eosin (H&E) staining (x100) showing two different tissues; normal thyroid tissue and a nodule with large clear cells (star).

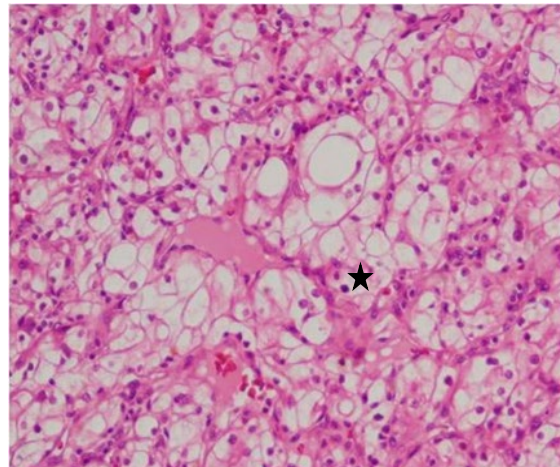


Figure 2 H&E staining (x300) showing clear cell carcinoma.

Her evaluation was completed in the consultations and revealed a 12 x 10 cm right kidney tumor that made contact with the right hemidiaphragm and the liver, compressing and displacing the vena cava and the portal vein.

The patient underwent open right nephrectomy plus cavotomy in June 2007. She was released to her home on postoperative day 6 with no complications.

The definitive anatomopathologic study stated Fuhrman 1 clear cell carcinoma, with extensive areas of necrosis and bleeding that infiltrated Gerota's capsule without surpassing it. The disease extended to the renal vein, affecting the edge of the tumor resection (pT4NxM1).

The patient did not receive adjuvant treatment and continues to be checked at our service. She has been disease-free for 8 years since the diagnosis of the metastatic kidney tumor. Follow-up protocol includes computed axial tomography scans of the chest, abdomen, and pelvis and serial laboratory studies according to the regimen recommended by the European Association of Urology (EAU).

Case 2: A 75-year-old woman had a past medical history of 5 births, high blood pressure (HBP), and diabetes mellitus (DM) treated with oral antidiabetic agents. She came to the emergency service of our hospital in September 2004 due to difficulty to urinate and symptoms of acute urinary retention associated with left renal/ureteral pain. Physical examination revealed a 2.4 x 2.5 cm, polypoid, pedunculated formation at the level of the urethra.

Imaging studies identified a large mass in the left kidney and the excretory tract was infiltrated with intra-aortic and para-aortic adenopathies and suspicion of thrombosis of the portal vein.

The patient underwent open left radical nephrectomy and surgical exeresis of the urethral caruncle. She was released to her home on postoperative day 4 with no complications.

The anatomopathologic study stated Fuhrman 2 clear cell adenocarcinoma in the left kidney that infiltrated the perirenal adipose tissue, with neoplastic thrombosis of the renal vein that reached the resection edge. The ure-

thral lesion was a tumor implant of the renal carcinoma (stage p T4N1M1) (figures 3 and 4).

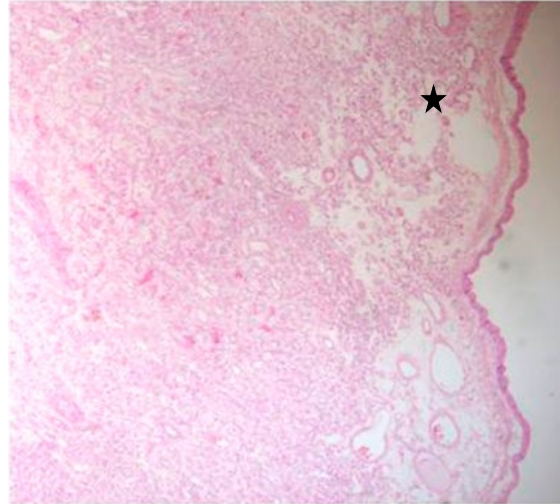


Figure 3 H&E staining (x100) showing normal genital skin infiltrated by clear cells (star).

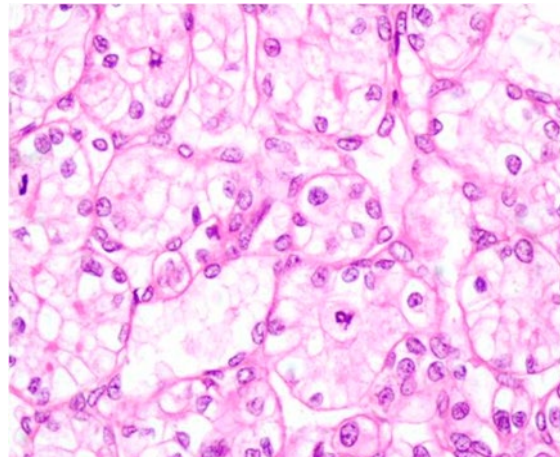


Figure 4 H&E staining (x400) showing Fuhrman 2 clear cell kidney tumor.

The patient did not receive adjuvant treatment and is currently disease-free, according to the EAU protocol, at follow-up of 11 years.

Case 3: A 64-year-old man had a past medical history of HBP, DM, hypercholesterolemia, and non-muscle-invasive bladder cancer. Several lesions consistent with left kidney tumor were identified in follow-up imaging studies.

The anatomopathologic study stated Fuhrman 2 clear pT1 adenocarcinoma (figures 5 and 6).

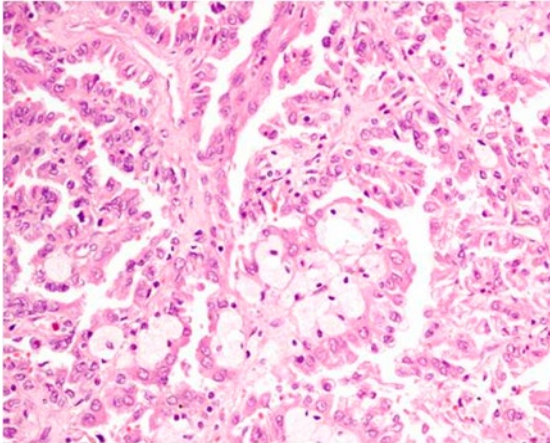


Figure 5 H&E staining (x300) of the resected bladder tissue showing the vascular axes with clear cells.

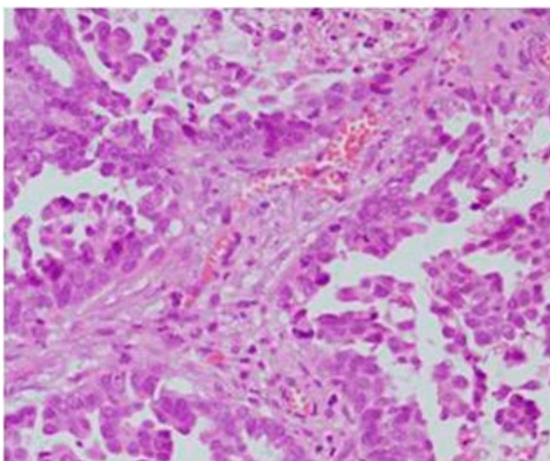


Figure 6 H&E staining (x400) showing the vascular axis more clearly.

A bladder lesion was found at follow-up and after its resection, the anatomopathologic study reported papillary clear cell renal cell carcinoma metastasis that infiltrated the mucosa, as well as pulmonary metastases. Treatment with sunitinib was begun, resulting in disease control after 8 months of treatment. The patient continues to be followed, according to the EAU regimen.

Discussion

The classic metastatic sites of kidney tumor are the lungs (50%), bone (49%), lymph nodes (6-32%), skin (11%), liver (8%), and brain (3%). The majority of metastases occur after the first 5 years, especially at the first 3 sites mentioned.

The thyroid gland is a frequent site of metastasis, but only 2.1% of malignant pathology of the thyroid gland is metastatic.⁽³⁾ Thirty-four percent of the metastases that affect the thyroid are from kidney tumors, 15% are from pulmonary tumors, 14% are from the gastrointestinal tract, 14% are from breast cancer, thus metastasis should be kept in mind as a cause of thyroid nodule. Metastases do not usually affect the hormone production of the gland. Thyroid puncture enables 90% of the cases of malignant thyroid disease to be correctly classified and only 58% of the cases are metastatic.⁽⁴⁾

The urethra is an uncommon tumor site and metastases at that location are even rarer. Metastases to the urethra have been described that originate from the colon, lungs, kidneys, and prostate,⁽⁵⁻⁶⁾ but described cases are scarce. The theories about the pathogenesis of kidney tumor metastases to the urethra are similar to those utilized to explain metastases to the bladder. The urinary tract is a possible dissemination route,⁽⁷⁾ based on the fact that tumor cells infiltrate the mucosa of the renal pelvis where they enter the urine, given the greater incidence of those tumors if the collecting system is perforated that has been described. Another theory is that the disease arises from retrograde tumor emboli. Further research is needed to determine the causes of those pathologies. Diagnosis can only be confirmed through biopsy, which can also be employed as treat-

ment. Those lesions require high clinical suspicion, especially if there is a history of interest.⁽⁷⁾

The finding of a metastatic tumor in the bladder is very rare and is believed to account for less than 2% of cases. The tumors that most produce bladder metastasis are: gastric adenocarcinoma, melanoma, and adenocarcinomas of the breast and colon. Kidney cancer with metastasis to the bladder is an extremely rare entity, with only 56 cases described in the medical literature.⁽⁸⁾ It can present more frequently as gross hematuria or as obstructive symptoms. Clear cell tumor is the histologic type of kidney cancer related to those metastases. Metastases can be synchronous (23%) or metachronous (77%) and the mean time between kidney tumor treatment and the appearance of bladder metastasis is 33 months.⁽⁹⁾

There are primarily three mechanisms described for metastasis to the bladder: hematogenic, lymphatic, and urinary. Hematogenic metastases can be produced by systemic circulation, which is currently the most well-known metastatic mechanism, or they can be produced in a retrograde manner, using the gonadal vein and metastasizing as retrograde tumor emboli. In lymphatic dissemination, the tumor cells reach the lymphatic system and take advantage of the interconnections between lymph vessels and blood vessels to spread. The urinary mechanism is based on the fact that carcinogenic cells have been found in the urine of patients with kidney tumor. It is a mechanism that acts through drop metastasis. However, metastasis in the ureter has not been demonstrated in patients with primary kidney tumor. In addition, those dissemination mechanisms can fuse with one another, creating complex combined mechanisms. Generally, bladder metastases from a kidney tumor indicate that the disease is extended and

has a poor prognosis, albeit cases of long-term survival have been described. The cancer-specific survival varies between 77 and 25%.⁽¹⁰⁾

The treatment of choice in cases of metastases is surgical extirpation, as long as they are resectable. If not, treatment is anti-angiogenic therapy, as described in the clinical practice guidelines.

Conclusion

Metastases to the thyroid, bladder, and the urethral caruncle are rare sites for metastases from kidney cancer and tend to indicate advanced disease stages. When resectable, their treatment is surgical extirpation.

References

1. Hock LM, Lynch J, Balaji KC. Increasing incidence of all stages of kidney cancer in the last 2 decades in the United States: an analysis of surveillance, epidemiology and end results program data. *J Urol*. 2002;167(1):57-60.
2. Frank I, Blute ML, Cheville JC, Lohse CM, Weaver AL, Leibovich BC, et al. A multifactorial postoperative surveillance model for patients with surgically treated clear cell renal cell carcinoma. *J Urol*. 2003;170(6):2225-32.
3. Villumsen AL, Mevik K, Fjøsne HE, Brekke MB, Haugen OA. Late onset metastases to the thyroid gland from renal carcinoma. *Tidsskr Den Nor Laegeforening Tidsskr Prakt Med Ny Raekke*. 2013;133(21):2262-5.
4. Medas F, Calò PG, Lai ML, Tuveri M, Pisano G, Nicolosi A. Renal cell carcinoma metastasis to thyroid tumor: a case report and review of the literature. *J Med Case Reports*. 2013;7(1):265.

5. Chitale SV, Burgess NA, Sethia KK, Love K, Roberts PF. Management of urethral metastasis from colorectal carcinomas. *ANZ J Surg.* 2004;74(10):925-7.
6. Tefilli MV, Stefani SD, Mariano MB. Urethral metastasis of lung carcinoma with germinative cell features. *Int Braz J Urol.* 2003;29(5):431-3. Available in: http://www.scielo.br/scielo.php?script=sci_abstract&pid=S1677-55382003000500008&lng=en&nrm=iso&tlng=en
7. Senzaki H, Okamura T, Tatsura H, Watase H. Urethral metastasis from renal cell carcinoma. *Int J Urol.*2003;10(12):661-3. Available in: <https://onlinelibrary.wiley.com/doi/abs/10.1046/j.1442-2042.2003.00717.x>
8. Gelister JS, Falzon M, Crawford R, Chapple CR, Hendry WF. Urinary tract metastasis from renal carcinoma. *Br J Urol.*1992;69(3):250-2.
9. Matsumoto K, Hayakawa N, Nakamura S, Oya M. Bladder metastasis from renal cell carcinoma: retrospective analysis of 65 reported cases. *Clin Exp Metastasis.* 2015;32(2):135-41. Available in: <http://europepmc.org/abstract/med/25630270>
10. Raviv S, Eggener SE, Williams DH, Garnett JE, Pins MR, Smith ND. Long-term survival after «drop metastases» of renal cell carcinoma to the bladder. *Urology.*2002;60(4):697.