



The role of laparoscopic surgery in the management of urinary lithiasis in the era of endourology in Mexico

Rol de la cirugía laparoscópica en el manejo de la litiasis urinaria en la era de la endourología en México

Gerardo Tena-González Méndez,¹
 Jean Carlos García-Escobar,¹
 Eduardo Jiménez-Cisneros,¹
 Miguel Maldonado-Ávila,¹
 Hugo Arturo Manzanilla-García,¹
 Víctor Enrique Corona-Montes,¹
 Leopoldo Mateo Garduño-Arteaga,¹
 Jorge Jaspersen-Gastelum,¹
 Jesús Emmanuel Rosas-Nava.¹

Abstract

Objective: The aim of the present study was to describe the results of a case series of laparoscopic pyelolithotomies and ureterolithotomies performed at the *Hospital General de México* and demonstrate that the laparoscopic management still has a place among the therapeutic options in our country.

Material and methods: Retrospective analysis on patients that underwent laparoscopic pyelolithotomy or laparoscopic ureterolithotomy, within the time frame of 2013 and 2022. Intraoperative variables of blood loss, surgery duration, and complications; and the postoperative variables of hospital stay, time to double-J stent removal, and complications were analyzed.

Results: 46 underwent laparoscopic pyelolithotomy and 29 underwent laparoscopic ureterolithotomy. Mean patient age was 45 years. Forty-three of the procedures were right-sided, 31 were left-sided, and there was one case of ectopic pelvic kidney. The pyelolithotomy results were: stone size of 24x20mm (8.8-60 x 5-60), 1034 HU, S.T.O.N.E. score of 6, surgery duration of 124 min, blood loss of 72ml, and hospital stay of 2.3 days. The ureterolithotomy results were: stone size of 22x11mm (10-80mm x 7.8-20), 980 HU, surgery duration of 101min, blood loss of 31ml, and hospital stay of 2.4 days. There were 3 intraoperative complications and 4 postoperative complications.

Conclusión: Laparoscopic surgery can be a feasible and reproducible alternative to endourologic management, with good results, in large volume (>20mm) single stones.

Keywords:

Pyelolithotomy, ureterolithotomy, laparoscopy, lithiasis

Corresponding author:

*Gerardo Tena-González Méndez. Address: Camino Santa Teresa 1055, apt. 937. Email: drtena.urologia@gmail.com

Citation: Tena-González Méndez, G., García-Escobar, J. C., Jiménez-Cisneros, E., Maldonado-Ávila, M., Manzanilla-García, H. A., Corona-Montes, V. E. et al. *The role of laparoscopic surgery in the management of urinary lithiasis in the era of endourology in Mexico. Rev Mex Urol.* 2024;84(4): 1-12

¹ Hospital General de México, "Eduardo Liceaga", Ciudad de México, México.

Accepted: July 31, 2024.

Received: January 17, 2024.



Resumen

Objetivo: El objetivo del estudio es describir los resultados de la serie de pielolitomías y ureterolitomías laparoscópicas del Hospital General de México.

Material y métodos: Análisis retrospectivo de pacientes operados de pielolitomía y ureterolitomía laparoscópica entre 2013 y 2022. Se analizaron el tamaño del lito, sangrado, tiempo quirúrgico, complicaciones, estancia intrahospitalaria, tiempo a retiro de catéter doble J y complicaciones.

Resultados: Fueron 46 pielolitomías y 29 ureterolitomías. 54% fueron hombres, con una media de edad de 45 años. Los resultados de las pielolitomías fueron: medidas promedio de los litos fueron de 24x20mm con 1034 UH y un puntaje STONE promedio de 6; tiempo quirúrgico promedio de 124 min, sangrado promedio de 72ml, con estancia promedio de 2.3 días. Las ureterolitomías mostraron una medida promedio de los litos fue de 22x11mm con 980 UH; tiempo quirúrgico promedio de 101min, sangrado promedio de 31ml, con estancia promedio de 2.4 días.

Conclusión: En litos únicos, de gran volumen (>20mm), tanto en uréter como pelvis renal, la cirugía laparoscópica puede ser una alternativa factible y reproducible al manejo endourológico con buenos resultados.

Palabras clave:

Pielolitomía,
ureterolitomía,
laparoscopia, litiasis

Introduction

Urinary lithiasis is an important health problem worldwide, with a growing prevalence in the past 25 years, and a global incidence of about 10 %.⁽¹⁾ Its prevalence and incidence vary according to age, sex, race, geographic location, climate, etc. The disease has a higher prevalence in men than in women (12 % vs 6 %) and there is a greater prevalence in the fifth decade of life.⁽²⁾

In Mexico, there are few epidemiologic reports on this disease, but we know it is a great national health problem, given that hospitalizations due to urolithiasis are reported at a mean 4.35 per 100 000 inhabitants. In addition, there are states, such as Yucatán, in which prevalence and incidence are much higher, at around 350 to 400 cases per year, with an annual hospitalization figure of 12.53 per 100 000 inhabitants.⁽³⁾

The treatment of urinary lithiasis has evolved importantly over the past decades, from open surgeries with large incisions and great damage to the renal parenchyma, such as occurs in anatomic nephrolithotomy, to minimally invasive procedures performed through 4.8 Fr tracts and with laser energy, such as occurs in micro-percutaneous nephrolithotomy.^(4,5)

The final goal in the management of urinary lithiasis is for the patient to be free of stones through the lowest number of procedures possible and with no complications.⁽⁶⁾ The current international guidelines recommend that management preferably be performed endoscopically or through extracorporeal shock wave lithotripsy (ESWL), the latter of which is not widely used in Mexico. Regarding endoscopic

management, the two standard procedures are ureteroscopy (URS) and percutaneous nephrolithotomy (PCNL). Management through one procedure or the other is determined by stone size and location.^(7,8) The guidelines also refer to laparoscopic, robotic, or open management, in cases in which endourologic access is not possible or has failed, such as in patients with anatomic anomalies: ectopic kidneys, ureteropelvic junction stricture, ureteral stricture, malrotations, etc.

Importantly, carrying out the abovementioned endoscopic procedures requires a large amount of fixed and disposable devices, such as ureteral catheters, double-J stents, ureteral sheaths, hydrophilic guidewires, semirigid ureteroscopes, flexible ureteroscopes, nephroscopes, dilators, extraction baskets, lasers, etc., resulting in a very costly procedure whose availability is often suboptimal.⁽⁹⁻¹¹⁾ Likewise, because the prevalence of lithiasis is so high in hospitals such as ours, there tends to be a long wait for surgery, which is also a problem for stone resolution in those patients.

Laparoscopy is a form of minimally invasive surgery that has been shown to provide faster recovery, less blood loss, less postoperative pain, and shorter hospital stay, compared with open surgery.⁽¹²⁾ It has increasingly greater availability, resulting in wider and more frequent use.

Therefore, it is relevant to present the results of the laparoscopic approach, as well as to demonstrate its feasibility and safety, considering it another option for the management of urinary lithiasis in Mexico.

The primary aim of the present study was to present the stone-free rate (SFR) and intraoperative and postoperative complication in patients that underwent laparoscopic pyelolithotomy (LP) or laparoscopic ureterolithotomy (LU) at the *Hospital General de México*, within the time frame of 2013 and 2022. The secondary aims were to describe the mean stone size for determining a large volume stone, surgery duration of the two procedures, and intraoperative blood loss.

Material and methods

Material and methods

A retrospective descriptive analysis was carried out on patients that underwent LP and LU between 2013 and 2022. The research was previously approved by the local Ethical Board Review (ID: 1015-220/22). We excluded patients under 18 years of age, that did not have a recent image study (less than 6 months), and those with incomplete clinical file. The decisions of performing these procedures were either the stone size, the lack of endoscopic materials or supplies, or prolonged waiting lists for endoscopic management. The latter due to the high volume demand of our third level hospital.

The demographic variables included age, sex, weight, height, body mass index, the presence or absence of comorbidities (arterial hypertension, diabetes mellitus, or chronic kidney disease), and a history of previous lithiasis and surgeries for its management (endoscopic, open, or laparoscopic); the lithiasis-related variables included laterality, location (renal pelvis, proximal ureter, middle ureter, distal ureter), complete or incomplete staghorn stone, length, width, density, and S.T.O.N.E. score, as well as whether the patient had a nephrostomy or double-J stent; the surgery-related variables included time from diagnosis to surgery, type of approach (transperitoneal or retroperitoneal), whether the procedure was

associated with ureteropelvic junction obstruction repair, if closure was performed with interrupted or continuous sutures, whether double-J stent and drainage were placed, blood loss, surgery duration, days of hospital stay, time at which urinary catheter was removed, and time at which double-J stent was removed. Likewise, immediate complications and those at 30 days and 90 days were analyzed and classified, utilizing the Clavien-Dindo classification.

The long-term follow-up included creatinine quantification, imaging studies, such as: CT scan, KUB or renal scintigraphy to look for recurrent lithiasis, residual stricture, or kidney function loss, defined as nephrectomy due to a non-functioning kidney, or hydronephrotic bag at follow-up.

The categorical variables were expressed through frequency and the ordinal and numerical variables through mean and median. Those patients with missing data at follow-up will be omitted on the follow up results.

The surgeries were performed by a single surgeon (JERN), who is a staff physician at the Urology Service of the *Hospital General*. The authors confirm the availability of, and access to, all original data reported in this study

Surgical technique

Once the pneumoperitoneum was achieved, a 12mm trocar was introduced through the incision. Two other 5 mm trocars were placed, using the triangulation technique. The colon was medialized through the white line of Toldt. The ureter was identified and carefully dissected distally and proximally, until reaching the site of the stone, whether in the ureter or renal pelvis. Blunt dissection was gently performed with the aspirator, given that the chronic inflammatory process caused by the stone weakens and thins the wall of the pelvis or ureter, with the risk of tear in either one.

After the site was identified, a longitudinal incision was made in the ureter, or transversal incision was made in the renal pelvis. The stone was distally stabilized with an intestinal forceps, while the hand manipulating the proximal ureter pushed and approximated the other hand, to extract the stone from the urinary tract, avoiding extending the incisions.

Once the stone was extracted, it was bagged to prevent its loss in the cavity. A double-J stent was placed, utilizing the cephalad trocar. Lastly, in the renal pelvis, closure was carried out with interrupted or continuous sutures in the same direction as when it was opened. In the ureter, transversal closure was performed, following the Heineke-Mikulicz principle, with 3 interrupted sutures, utilizing polyglecaprone 25 (Monocryl[®]) on a 4-0 SH non-cutting needle. A drain was placed, and the ports were closed (Image 1, pyelolithotomy and image 2, ureterolithotomy).

Image 1

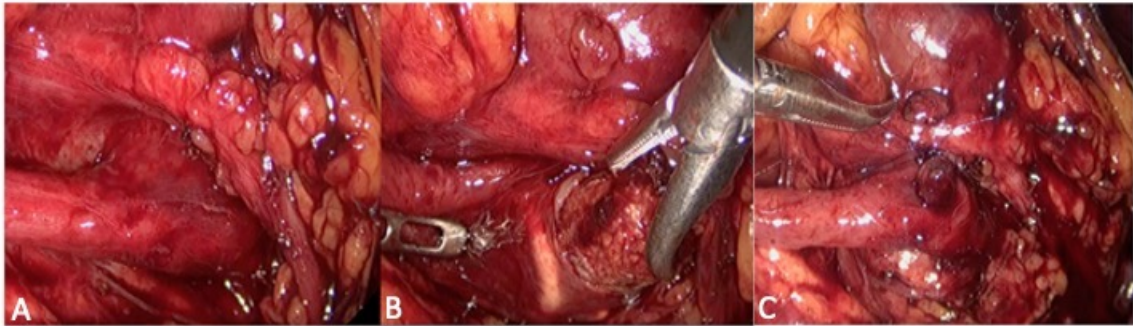
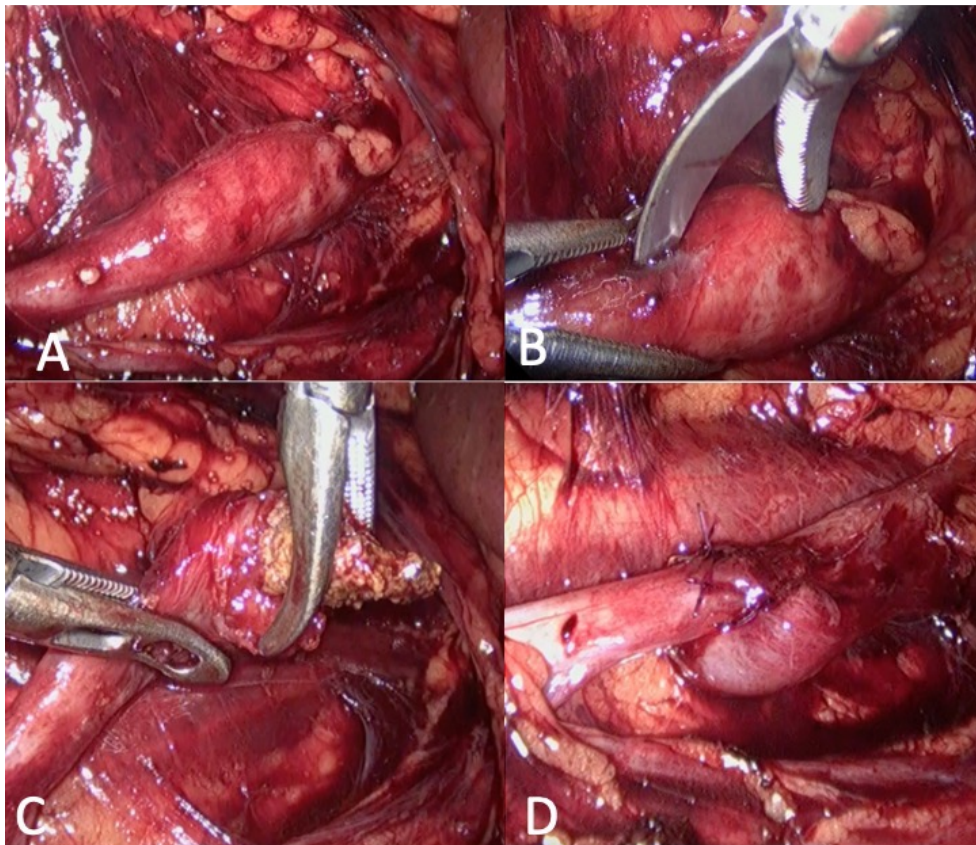


Image 2



Results

Ninety patients underwent LP or LU, within the time frame of 2013 and 2022, and 75 of them had the most variables to analyze. Thirty-five of the patients were women, 40 were men, and mean patient age was 45 years (18-72 years). All the surgeries were transperitoneal procedures, as described above.

Forty-three surgeries were right-sided, 31 were left-sided, and there was 1 case of ectopic pelvic kidney. Forty-six of the 75 surgeries were LPs (2 in horseshoe kidney), 13 of which were associated with ureteropelvic junction repair. Twenty-nine surgeries were LUs (28 in the proximal ureter and 1 in the middle ureter).

The SFR in the LPs was 91 %, with 4 patients having residual stones; they were calyceal stones that could not be extracted during that surgery time, but the main pelvic stone was completely extracted. The SFR in the LUs was 100 %, with respect to the stone obstructing the urinary tract. Table 1 shows the intraoperative laparoscopic pyelolithotomy results and Table 2 shows intraoperative laparoscopic ureterolithotomy results.

Table 1. Intraoperative laparoscopic pyelolithotomy results

Variable	Results
Surgery duration (min)	124 (60-220)
Mean blood loss (ml)	72 (10-210)
Mean stone size (mm)	24x20mm (8.8-60 x 5-60)
Mean S.T.O.N.E. score	6 (5-11)
Mean Hounsfield Units	1034 (803-1417)
Hospital stay (days)	2.3 (2-3 días)
Stone-free rate	96 %

Table 2. Intraoperative laparoscopic ureterolithotomy results

Variable	Results
Surgery duration (min)	101 (60-180)
Mean blood loss (ml)	31 (5-80)
Mean stone size (mm)	22x11mm (10-80mm x 7.8-20)
Mean Hounsfield Units	980 (462-1240)
Hospital stay (days)	2.4 (2-5)
Stone-free rate	100 %

A urinary catheter and Penrose drain were placed in all 75 patients and a 6Fr x 24cm double-J stent was placed in 74. The Foley catheter was removed at a mean 33 postoperative hours and the double-J stent at a mean 4.5 weeks after the procedure.

There were three intraoperative complications: bleeding secondary to a gonadal vein tear, bleeding due to epigastric vessel injury during laparoscopic port placement, and loss of a stone in the abdominal cavity. Postoperatively, there were two Clavien-Dindo I complications: the formation of an intrarenal clot associated with renal-ureteral colic, before 30 days, and an incisional hernia found at 90 days at the follow-up consultation; and two Clavien-Dindo III or higher complications: a urinary leak in the immediate postoperative period that required double-J stent placement and a forgotten double-J stent with a calcified proximal curl, requiring PCNL for its removal.

Despite, the follow-up could not be standardized due to patient saturation of both urology clinic and radiology. We only obtained follow-up of 32 patients either with creatinine and imaging studies such as CT scans, KUB, Kidney ultrasounds, or renal scintigraphy, in a range of 3 to 48 months. After the LP procedure, three of the patients that underwent ureteropelvic junction repair presented with recurrent stricture and only one patient presented with long-term kidney function loss.

Discussion

Today, the trend in all branches of surgery is to perform increasingly less invasive procedures, and urology is no exception. Endourology has become the standard treatment for lithiasis

management because it resolves as high as 90 % of cases, with short hospitalizations or outpatient procedures and low complication rates.⁽¹³⁾ Despite those advantages, there are factors that increase the risk for complications during an endoscopic procedure, such as stone size and location, as well as equipment availability, correct use of materials, and the skill and training of the urologist.⁽¹⁴⁾ In the CROES study, which has the largest international and multicenter cohort of patients with lithiasis, with 11 885 patients that underwent URS, an overall SFR of 85 % was demonstrated, along with a SFR of 59.8 % in the cases that presented with intraoperative complications. The overall complication rate was 7.4 %, and the most frequent complications were fever, failed procedures, and bleeding.⁽¹⁵⁾ Likewise, regarding PCNL in that same study, the SFR was only 75.7 % and 14.5 % of those patients experienced some kind of intraoperative or postoperative event. Among the reported complications, 7.8 % of patients had bleeding, 3.4 % had perforation of the renal pelvis, 1.8 % presented with hydrothorax, and the procedure could not be completed in 99 cases.⁽¹⁶⁾

The majority of documented case series tend to be conducted at hospitals that have all the necessary resources and devices in the best condition. In those analyses, a ureteral stone or kidney stone is considered large volume starting at 10mm and at 20 mm, respectively, which are the cutoff points utilized in the current management guidelines.⁽¹⁷⁾ In Mexico, ureteral stones have been found as large as 8cm and pelvic stones up to 6cm at hospitals with limited resources, at times leading to the indiscriminate use of the semi-rigid ureteroscope in the treatment of such large stones in the ureter and renal pelvis. In addition, the open

approach continues to be an option, despite the comorbidities it entails.

In the comparative study of open pyelolithotomy versus LP by Hassan *et al.*, surgery duration was longer with the laparoscopic approach (78.13 min vs 117.66 min), but there was less blood loss, a lower transfusion rate, and a lower overall complication rate (29.26 % vs. 12.12 %). The most frequent complication with the open approach was surgical wound infection (14.63 %), followed by ileus (4.87 %), pneumonia (2.4 %), urinary tract infection (2.4 %), and postoperative fever (2.4 %). The most frequent complication with the laparoscopic approach was postoperative fever (9.09 %), followed by urinary tract infection (3.03 %). Hospital stay was also longer with the open approach (6.74 days vs 3.77 días).⁽¹⁸⁾

Laparoscopy has been developed as a widely used minimally invasive surgical technique in urology and has a place in the management of lithiasis. For example, clear indications for its use are pelvic stones associated with ureteropelvic junction stricture, given that the two situations can be resolved in the same procedure; patients with failed URS due to stricture of impacted stones that are difficult to access; extremely obese patients, when sufficiently long PCNL sheaths are not available; ectopic kidneys; or when the calyceal anatomy does not favor access for percutaneous management.⁽¹⁹⁾

There is evidence on the use of laparoscopy and its advantages for the management of lithiasis disease.

With respect to stones in the renal pelvis, Bai *et al.* conducted a systematic review of 14 studies on the management of large volume stones in the renal pelvis, comparing LP and PCNL. There was a higher SFR using the laparoscopic approach (97.57 % vs 87.92 %,

$p=0.001$), with less use of auxiliary or retreatment procedures, such as ESWL or URS (0.24, 95 % CI 0.12- 0.46, $p=0.001$). The laparoscopic approach also resulted in a lower transfusion rate, less blood loss, and fewer cases of postoperative fever, but longer surgery duration.⁽²⁰⁾

In 2022, Duarsa *et al.* carried out a meta-analysis comparing LP and PCNL for the treatment of pelvic stones >15mm. In 16 of the studies evaluated, the SFR was higher with the laparoscopic approach, surgery duration was longer, the complication rate was lower, there was less decrease in hemoglobin, and the transfusion rate was lower. Likewise, the laparoscopic approach provided greater lithiasis resolution with no additional procedures (ESWL, URS, etc.), compared with PCNL (12 vs 38).⁽²¹⁾

In 2017, Wu *et al.* conducted a systematic review, comparing LU with URS and PCNL for the management of stones >10mm in the proximal ureter. Those authors concluded that resolution with a better SFR was greater in LU and PCNL than in URS, surgery duration was longer with the laparoscopic approach, and there was no impact on hospital stay between URS and LU.⁽²²⁾

Choi *et al.* compared LU and flexible retrograde URS for stones measuring 15mm or more in the proximal ureter and demonstrated that the laparoscopic approach resulted in longer surgery duration (128.5 ± 5.7 min vs. 49.7 ± 2.2 min, $p=0.001$), but a higher SFR (100 % vs. 73.1 %). Hospital stay was 6.7 days with LU versus 4.9 days with URS, concluding that LU is the best alternative for stones larger than 15mm that are impacted in the proximal ureter.⁽²³⁾

In 2020, Güler and Erbin compared LU versus retrograde URS versus anterograde URS for stones >15mm in the proximal ureter.

With close to 40 patients per group and stones larger than 20mm at their greatest diameter in the proximal ureter, there was resolution of 97.4 % cases with anterograde URS, 97.5 % with LU, and 83.7 % with retrograde URS; more auxiliary procedures were required with retrograde URS. Surgery duration was longer with the laparoscopic approach (147 min) versus 44 min in anterograde URS versus 60.1 min in retrograde URS and the laparoscopic approach had a lower complication rate. Thus, anterograde URS and LU are adequate alternatives for the management of those types of stones.⁽²⁴⁾ A summary of the comparing studies are presented in Table 3.

Table 3. Study comparison

Study	Comparison	Stone size / location	Stone-free rate at 1 month	Surgery duration	Additional procedure	Hospital stay	Complications (patients)
Jae Duck Choi <i>et al.</i> (2019). ⁽²³⁾	LU (48) vs URS (52)	>1.5cm/proximal ureter	100 % vs 73.1 %	128 vs 49	0 % vs 27 %	6.7 vs 4.9	6 vs 10
Yunjin Bai, <i>et al.</i> (2017). ⁽²⁰⁾	LP vs PCNL	>2cm	97.57 % vs 87.92 %	Longer in LP	Additional ESWL 6.54 % vs 18.44 %	Shorter in PCNL	Fewer in LP
Wirya Kusuma, <i>et al.</i> (2022). ⁽²¹⁾	LP vs PCNL	-	Greater in LP (p 0.0001)	Longer in LP	12 vs 38 patients	No difference	Fewer in LP
Lai, <i>et al.</i> (2020). ⁽²⁵⁾	LU vs URS LU vs PCNL	-	Greater in LU = LU vs PCNL	Shorter in URS = LU vs PCNL	More in URS	Shorter in URS = LU vs PCNL	Urinary leak = between LU and PCNL Similar overall complications

Even though we did not compare URS or PCNL in the present work due to data lacking on postPCNL patient follow-up, we found that the SFR was very similar to that of other studies, with 100 % in ureteral stones and 91% in pelvic stones, due to the fact that the residual stones were in the calyces and could not be removed by ureteroscope or flexible cystoscope. Likewise, surgery duration was slightly shorter than that reported, with 124 min (60-220 min) in LP and 101 min (60-180min) in LU. Mean blood loss was minimal in both surgeries and hospital stay was 2.4 days. Catheter removal was carried out at a mean 33 hours and double-J stent removal at a mean 4.5 weeks. Table 3 shows the existing comparative studies.

We had 3 intraoperative complications: one defect in the energy seal of the gonadal vein that required the placement of a vascular intracorporeal prolene suture; one case of a stone lost in the cavity that we could not find, despite carrying out intraoperative radiography; and one case of laparoscopic port bleeding at the beginning of the surgery that was resolved with a transfixion suture to control the epigastric vessels. We had an overall postoperative complication rate of 5 %, 2.6 % of which were Clavien-Dindo III or higher. One of those complications was a urinary leak; in that case, we had decided not to place a double-J stent, but resolved the leak by placing a double-J stent under direct vision with a semi-rigid ureteroscope. Another complication was a calcified proximal curl of a double-J stent that was not removed at 6 weeks but left in for 3 months, requiring PCNL. Of the long-term complications, 3 patients associated with ureteropelvic junction repair presented with re-stenosis and one patient presented with kidney function loss.

Of our study limitations, the main one was its retrospective design and consequential loss of information. Likewise, 43 patients were lost to follow-up, given that we had laboratory and imaging data for only 32 patients during that period.

Conclusion

In stones larger than 20mm in the proximal ureter and renal pelvis, LU and LP, respectively, are a feasible, safe, and reproducible alternative for the efficacious resolution of such stones, when complete and adequate material are not available and experience for performing the endourologic approach is lacking. LU and LP

offer high SFRs and low complication rates, but more comparative and prospective studies are needed versus PCLN and URS at our institution to reach better conclusions.

CRediT Taxonomy

1. **Gerardo Tena-González Méndez:** (I) Conception and design; (IV) Collection and assembly of data; (VI) Manuscript writing; (VII) Final approval of manuscript.
2. **Jean Carlos García-Escobar:** (IV) Collection and assembly of data; (VI) Manuscript writing; (VII) Final approval of manuscript.
3. **Eduardo Jiménez-Cisneros:** (V) Data analysis and interpretation; (VI) Manuscript writing; (VII) Final approval of manuscript.
4. **Miguel Maldonado-Ávila:** (V) Data analysis and interpretation; (VI) Manuscript writing; (VII) Final approval of manuscript.
5. **Hugo Arturo Manzanilla-García:** (III) Provision of study materials or patients; (VI) Manuscript writing; (VII) Final approval of manuscript.
6. **Víctor Enrique Corona-Montes:** (II) Administrative support; (VI) Manuscript writing; (VII) Final approval of manuscript.
7. **Leopoldo Mateo Garduño-Arteaga:** (II) Administrative support; (VI) Manuscript writing; (VII) Final approval of manuscript.
8. **Jorge Jaspersen-Gastelum:** (II) Administrative support; (VI) Manuscript writing; (VII) Final approval of manuscript.
9. **Jesús Emmanuel Rosas-Nava:** (III) Provision of study materials or patients; (VI) Manuscript writing; (VII) Final approval of manuscript.

Conflict of interest

None of the authors have any conflicts of interest or financial ties to disclose.

Funding

This research received no specific grant from any funding agency in the public, commercial, or not-for-profit sectors.

References

1. Rukin NJ, Siddiqui ZA, Chedgy ECP, Somani BK. Trends in Upper Tract Stone Disease in England: Evidence from the Hospital Episodes Statistics Database. *Urologia Internationalis*. 2017;98(4): 391–396. <https://doi.org/10.1159/000449510>.
2. Curhan GC. Epidemiology of Stone Disease. *The Urologic clinics of North America*. 2007;34(3): 287–293. <https://doi.org/10.1016/j.ucl.2007.04.003>.
3. Ortégón-Gallareta R, Aguilar-Moreno J, Álvarez-Baeza A, Méndez-Domínguez N, Pech-Cervantes PI. Perfil epidemiológico de las hospitalizaciones por urolitiasis en el Estado de Yucatán, México. *Revista Mexicana de Urología*. 2019;79(5): 1–11. <https://doi.org/10.48193/revistamexicanadeurologia.v79i5.517>.
4. Shah J, Whitfield HN. Urolithiasis through the ages. *BJU international*. 2002;89(8): 801–810. <https://doi.org/10.1046/j.1464-410x.2002.02769.x>.
5. Jones P, Elmussareh M, Aboumarzouk OM, Mucksavage P, Somani BK. Role of Minimally Invasive (Micro and Ultra-mini) PCNL for Adult Urinary Stone Disease in the Modern Era: Evidence from a Systematic Review. *Current Urology Reports*. 2018;19(4): 27. <https://doi.org/10.1007/s11934-018-0764-5>.
6. Ng ACF, Wong MYC, Isotani S, Practical Management of Urinary Stone. Singapore: Springer; 2021. <https://doi.org/10.1007/978-981-16-4193-0>.
7. European Association of Urology. EAU Guidelines on Urolithiasis. 2022 <https://uroweb.org/guidelines/urolithiasis>
8. American Urological Association. Kidney Stones: Surgical Management Guideline. 2022
9. Doizi S, Traxer O. Flexible ureteroscopy: technique, tips and tricks. *Urolithiasis*. 2018;46(1): 47–58. <https://doi.org/10.1007/s00240-017-1030-x>
10. Proietti S, Rodríguez-Socarrás ME, Eisner B, De Coninck V, Sofer M, Saitta G, et al. Supine percutaneous nephrolithotomy: tips and tricks. *Translational Andrology and Urology*. 2019;8(Suppl 4): S381–S388. <https://doi.org/10.21037/tau.2019.07.09>.
11. Bayne DB, Chi TL. Assessing Cost-Effectiveness of New Technologies in Stone Management. *The Urologic Clinics of North America*. 2019;46(2): 303–313. <https://doi.org/10.1016/j.ucl.2018.12.011>.
12. Yadav R, Kumar R, Hemal AK. Laparoscopy in the management of stone disease of urinary tract. *Journal of Minimal Access Surgery*. 2005;1(4): 173–180. <https://doi.org/10.4103/0972-9941.19264>.
13. Hejj R, McNulty M, Calleary JG, Hejj R, McNulty M, Calleary JG. Urology: The Home of Endoscopy. In: *Advances in Endoscopic Surgery*. IntechOpen; 2011. <https://doi.org/10.5772/24729>.
14. Al-Awadi K, Kehinde EO, Al-Hunayan A, Al-Khayat A. Iatrogenic ureteric injuries: incidence, aetiological factors and the effect of early management on subsequent outcome. *International Urology and Nephrology*. 2005;37(2): 235–241. <https://doi.org/10.1007/s11255-004-7970-4>

15. **de la Rosette J, Denstedt J, Geavlete P, Keeley F, Matsuda T, Pearle M, et al.** The clinical research office of the endourological society ureteroscopy global study: indications, complications, and outcomes in 11,885 patients. *Journal of Endourology*. 2014;28(2): 131–139. <https://doi.org/10.1089/end.2013.0436>.
16. **de la Rosette J, Assimos D, Desai M, Gutierrez J, Lingeman J, Scarpa R, et al.** The Clinical Research Office of the Endourological Society Percutaneous Nephrolithotomy Global Study: indications, complications, and outcomes in 5803 patients. *Journal of Endourology*. 2011;25(1): 11–17. <https://doi.org/10.1089/end.2010.0424>.
17. **Simforoosh N, Aminsharifi A.** Laparoscopic management in stone disease. *Current Opinion in Urology*. 2013;23(2): 169–174. <https://doi.org/10.1097/MOU.0b013e32835d307f>.
18. **Hassan Y, Rather AA, Bashir A, Wani IA, Rasool H.** Comparative Study of Laparoscopic and Open Pyelolithotomy in the Management of Large Renal Pelvic Stones. *Ibnosina Journal of Medicine and Biomedical Sciences*. 2022;14: 022–027. <https://doi.org/10.1055/s-0042-1749143>.
19. **Hamid CA, Ankur S, Sathish R.** Laparoscopic management of urinary tract calculi: uncommon but effective alternative to open surgery in certain situations. *International Archives of Integrated Medicine*. 2019;6(5)
20. **Bai Y, Tang Y, Deng L, Wang X, Yang Y, Wang J, et al.** Management of large renal stones: laparoscopic pyelolithotomy versus percutaneous nephrolithotomy. *BMC urology*. 2017;17(1): 75. <https://doi.org/10.1186/s12894-017-0266-7>
21. **Kusuma Duarsa GW, Wisnu Tirtayasa PM, Pramana IBP, Yudiana IW, Santosa KB, Oka AAG.** Meta-Analysis of Laparoscopic Pyelolithotomy versus Percutaneous Nephrolithotomy as a Treatment of Large Kidney Stones. *Open Access Macedonian Journal of Medical Sciences*. 2022;10(F): 113–121. <https://doi.org/10.3889/oamjms.2022.8122>.
22. **Wu T, Duan X, Chen S, Yang X, Tang T, Cui S.** Ureteroscopic Lithotripsy versus Laparoscopic Ureterolithotomy or Percutaneous Nephrolithotomy in the Management of Large Proximal Ureteral Stones: A Systematic Review and Meta-Analysis. *Urologia Internationalis*. 2017;99(3): 308–319. <https://doi.org/10.1159/000471773>.
23. **Choi JD, Seo SI, Kwon J, Kim BS.** Laparoscopic Ureterolithotomy vs Ureteroscopic Lithotripsy for Large Ureteral Stones. *JLS: Journal of the Society of Laparoendoscopic Surgeons*. 2019;23(2): e2019.00008. <https://doi.org/10.4293/JLS.2019.00008>
24. **Güler Y, Erbin A.** Comparative evaluation of retrograde intrarenal surgery, antegrade ureterorenoscopy and laparoscopic ureterolithotomy in the treatment of impacted proximal ureteral stones larger than 1.5 cm. *Central European Journal of Urology*. 2021;74(1): 57–63. <https://doi.org/10.5173/ceju.2021.0174.R1>.
25. **Lai S, Jiao B, Diao T, Seery S, Hu M, Wang M, et al.** Optimal management of large proximal ureteral stones (>10 mm): A systematic review and meta-analysis of 12 randomized controlled trials. *International Journal of Surgery*. 2020;80: 205–217. <https://doi.org/10.1016/j.ijssu.2020.06.025>