



Eosinophilic cystitis in pediatric age. Case review

Cistitis eosinofílica en la edad pediátrica. Revisión de caso

Jenny Elizabeth Arboleda-Bustán,^{1,2*} Pamela Reyes-Jurado,² María Fernanda Vicuña-Pozo,²
Jorge García-Andrade,² Marcelo Toro-Arias.²

Abstract

Eosinophilic cystitis (EC) is a rare disease that is characterized by inflammation of the bladder wall and whose etiology is still not well known. Less than 30 cases have been reported in the pediatric age. The symptoms, laboratory tests, and imaging studies are usually nonspecific, so the definitive diagnosis is by histopathology. Treatment, in most cases, is conservative (antihistamines, anti-inflammatories).

We present two cases of patients diagnosed with eosinophilic cystitis which appeared to be a bladder tumor in the initial evaluation. The diagnosis was confirmed by histopathological study after taking a sample of the tissue during cystoscopy. Both patients maintained conservative treatment remitting all their symptoms. Two years later patients remain asymptomatic.

As there are few reports in literature these clinical cases are presented to share our experience regarding clinical manifestations, diagnosis, and management of eosinophilic cystitis.

Keywords:

Eosinophilic
cystitis, pediatric,
inflammation, bladder

Citation: Arboleda Bustan J. E., Reyes Jurado P., Vicuña-Pozo M. F., García-Andrade J., Toro-Arias M. *Eosinophilic cystitis in pediatric age. Case review. Rev Mex Urol.* 2023;83(5):pp. 1-6

Corresponding author:

*Jenny Elizabeth Arboleda
Bustán. Address: Mariana
de Jesús Av., 170521,
Quito, Ecuador. Email:
elizabethab2011@gmail.
com

¹ Hospital Metropolitano, Quito, Ecuador

² Hospital Pediátrico Baca Ortiz, Quito, Ecuador

Received: May 15, 2023

Accepted: October 4, 2023



Resumen

La cistitis eosinofílica (CE) es una enfermedad rara que se caracteriza por la inflamación de la pared de la vejiga y cuya etiología aún no se conoce bien. Se han notificado menos de 30 casos en la edad pediátrica. Los síntomas, pruebas de laboratorio y estudios de imagen suelen ser inespecíficos, por lo que el diagnóstico definitivo es por histopatología. El tratamiento, en la mayoría de los casos, es conservador (antihistamínicos, antiinflamatorios).

Presentamos dos casos de pacientes diagnosticados de cistitis eosinofílica que en la evaluación inicial parecieron un tumor vesical. El diagnóstico se confirmó mediante estudio histopatológico tras la toma de muestra del tejido durante la cistoscopia. Ambos pacientes mantuvieron tratamiento conservador remitiendo todos sus síntomas. Dos años después los pacientes permanecen asintomáticos.

Debido a que existen pocos reportes en la literatura, se presentan estos casos clínicos para compartir nuestra experiencia con respecto a las manifestaciones clínicas, el diagnóstico y el manejo de la cistitis eosinofílica.

Palabras clave:

Vasectomía, erección,
IIEF

Introduction

Eosinophilic cystitis (EC) is a condition characterized by inflammation of the bladder wall resulting from the infiltration of eosinophils in its walls.⁽¹⁾ It is a rare pathology in children, and its etiology is not yet completely clear.⁽²⁾ Approximately 30 cases have been reported in literature.⁽¹⁾ Within the differential diagnosis, bladder sarcoma should be considered.⁽³⁾ At clinical level, variable manifestations are evident, from mild to severe depending on whether the pathology is acute, chronic, or recurrent.^(1,2) The experience obtained in two pediatric patients with abdominal pain, dysuria and an infiltrative lesion in the bladder is reported below.⁽²⁾

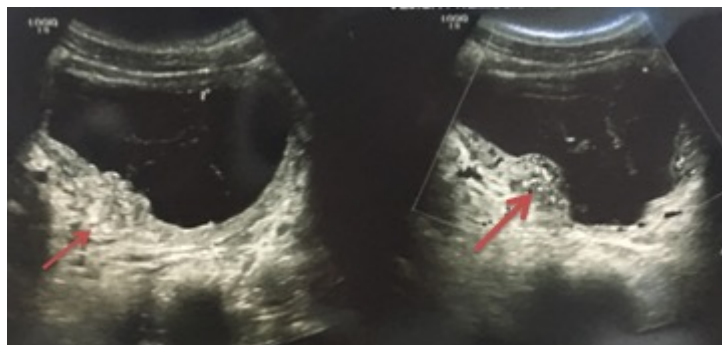Case Report

Case 1

An 11-year-old male patient, born and residing in Quito, Pichincha, was hospitalized due to the presence of macroscopic hematuria accompanied by moderately intense dysuria. No relevant personal or family medical history was reported. During the physical examination, tenderness was noted on palpation in the hypogastric region. The complete blood count and electrolyte levels were within the normal range. Urinalysis revealed a significant presence of blood +++++, with 409 red blood cells per high-power field (RBC/HPF), and a high level of proteins +++. Gram staining was negative.

Ultrasound showed a bladder that was not very distensible, with thickened walls, hypoechoic (0.85 cm), and the presence of fine internal septa with anechoic content and few internal echoes inside (Figure 1).

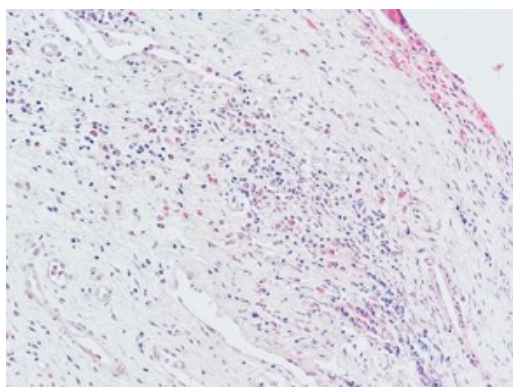
Figure 1. Ultrasound: bladder with thickened walls, hypoechoic, with internal septa with anechoic content inside



Simple and contrast-enhanced uro-tomography showed a detrusor muscle with irregular borders and concentric thickening of the wall, particularly in the posterior basal aspect, which became more pronounced when contrast was administered.

Cystoscopy revealed edematous, erythematous, and polypoid lesions. A biopsy was taken from the bladder mucosa. Histopathological analysis confirmed eosinophilic cystitis by observing a transmural inflammatory process with a predominance of eosinophils (more than 40 per large field increase), with a greater concentration in the lamina propria (Figure 2).

Figure 2 Diffuse infiltration of the lamina propria by eosinophils and cytoplasmic granules



Hematoxylin-eosin, x20

This met the Yamada and Taguchi criteria for eosinophilic inflammation, which require the presence of 20 or more eosinophils per 5

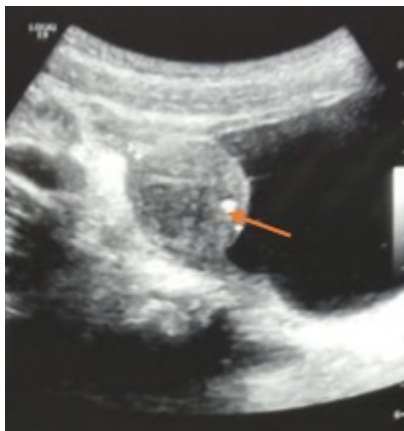x 20 fields. The patient was hospitalized for 7 days until he no longer had hematuria. In the follow-up ultrasound, no bladder mass was observed, and there was no recurrence of hematuria.

Case 2

A male patient, 8 years old, born and residing in Loja, was hospitalized due to the presentation of macroscopic hematuria without an apparent cause. There were no relevant personal or family medical history. On physical examination, tenderness was found in the hypogastric region. Complete blood count and electrolyte levels were within normal ranges. Urinalysis

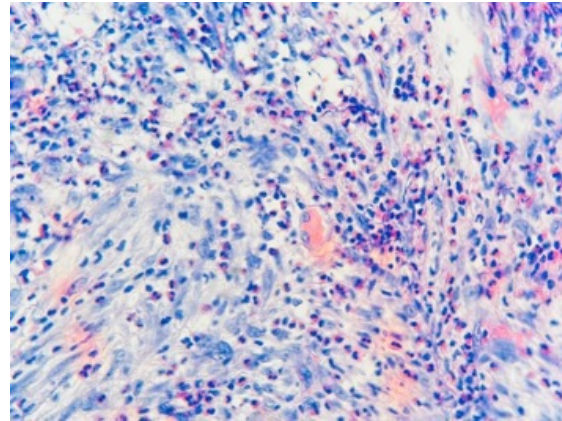
showed a significant presence of blood (++) , with 415 red blood cells per high-power field (RBC/HPF), and a high level of proteins (+++). Gram staining was negative. Ultrasound revealed the presence of a solid mass with well-defined borders in the bladder, of sessile shape, with both central and peripheral vascularity, and a heterogeneous structure (Figure 3). Magnetic resonance imaging, both simple and contrast-enhanced, of the pelvis showed a lobulated solid mass originating from the right lateral wall of the bladder, with dimensions of 19x22x20 mm.

Figure 3. Ultrasound: Mass with defined borders in the bladder



During cystoscopy, the bladder was observed to have trabeculated walls with a mildly arboriform proliferation, as well as a mass protruding from the right wall of the bladder. A biopsy of the bladder wall mucosa was performed, and the histopathological report indicated the presence of eosinophilic cystitis, with a polymorphonuclear and lymphocytic inflammatory infiltrate, secondary follicle formation, and the presence of multinucleated giant cells (Figure 4).

Figure 4. Diffuse infiltrate of the lamina propria with eosinophils (more than 40 per high-power field) and cytoplasmic granules



Hematoxylin-eosin, x40

The patient remained hospitalized for 5 days and received treatment with antimuscarinics at a dose of 0.1 mg/kg/day, after which he was discharged. One year later, he remains asymptomatic. A follow-up ultrasound was requested, which showed no thickening of the bladder wall, leading to a referral for further evaluation.

Discussion

Eosinophilic cystitis is an inflammatory pathology of uncertain origin that is reported in less than 150 adults and less than 30 children.⁽⁴⁾ Although the clinic is variable, most patients report irritative voiding symptoms, including dysuria, tenesmus, urgency, hematuria, and suprapubic pain and in some cases it is accompanied by a mass in the bladder.^(1,2,5) The disorder is considered to result from antigenic stimulation that promotes IgE-mediated attraction of eosinophils,⁽²⁾ which results in rupture of the lysosomal membrane, causing destruction of the bladder wall and release of inflammatory mediators.⁽⁶⁾

Imaging studies can sometimes make the diagnosis confusing, as if the mass would be an infiltrative tumor, as occurred in one of the cases. In ultrasound it can present as a concentric or focal thickening of the bladder wall; while in the magnetic resonance the polypoid projection towards the bladder can be seen, making the diagnosis more probable.⁽⁷⁾

Cystoscopy with biopsy is within the recommended international guidelines for diagnosis;⁽⁸⁾ since the histopathological result determines it. Eosinophilic infiltration of the lamina propria and muscularis mucosa should be found during the acute phase; unlike the chronic phase in which various degrees of fibrosis will be observed.⁽⁹⁾

The treatment is still not defined due to the unknown etiology and variable symptomatology. Nevertheless, the consensus is a conservative treatment, most of the cases reported in literature are of patients managed with antihistamines and anticholinergics, obtaining a favorable response.⁽¹⁰⁾

Although the pathology is generally benign, in some cases it may not slow down and cause complete fibrosis of the bladder prompting secondary uropathic obstruction.⁽¹¹⁾

Conclusion

Eosinophilic cystitis is an unusual disease in children that can be confused with an infiltrative tumor, requiring biopsy to differentiate them. It is important to have knowledge of the pathology to be able to suspect it, which is why we share our experience with these cases.

CRedit taxonomy

Jenny Arboleda Bustán: Conceptualization, research, formal analysis, writing of the article and review, supervision and validation

Pamela Reyes Jurado: Translation and data collection

María Fernanda Vicuña Pozo: Data collection

Jorge García Andrade: Head of service, validation

Marcelo Toro Arias: Review of pathology plates.

Acknowledgments: Thanks the people who collaborated in the work to present this work.

Conflict of interest

None of the authors have any conflicts of interest or financial ties to disclose.

Funding

This research received no specific grant from any funding agency in the public, commercial, or not-for-profit sectors.

References

1. **Abilov A, Özcan R, Polat E, Dervişoğlu S, Emir H.** Rare cause of dysuria: Eosinophilic cystitis. *Journal of Pediatric Urology.* 2013;9(1):e6–8. doi: <https://doi.org/10.1016/j.jpurol.2012.04.005>
2. **Pomeranz A, Eliakim A, Uziel Y, Gottesman G, Rathaus V, Zehavi T, et al.** Eosinophilic cystitis in a 4-year-old boy: successful long-term treatment with cyclosporin A. *Pediatrics.* 2001;108(6):E113. doi: <https://doi.org/10.1542/peds.108.6.e113>
3. **Yamada T, Taguchi H.** [Clinical study of interstitial cystitis. I-(I). The clinical and pathological observations of the contracted bladder caused by interstitial cystitis and tuberculosis]. *Nihon Hinyokika Gakkai Zasshi.* 1984;75(4):638–45.
4. **Thompson RH, Dicks D, Kramer SA.** Clinical manifestations and functional outcomes in children with eosinophilic cystitis. *Journal of Urology.* 2005;174(6):2347–9. doi: <https://doi.org/10.1097/01.ju.0000180423.06285.72>
5. **Schmitz-Dräger BJ, Skutetzki A, Rieker RJ, Schwab SA, Stöhr R, Bismarck E, et al.** Eosinophilic cystitis mimicking bladder cancer—considerations on the management based upon a case report and a review of the literature. *Virchows Arch.* 2021;479(3):523–7. doi: <https://doi.org/10.1007/s00428-021-03049-x>
6. **Zhou AG, Amin A, Yates JK, Diamond DA, Tyminski MM, Badway JA, et al.** Mass Forming Eosinophilic Cystitis in Pediatric Patients. *Urology.* 2017;101:139–41. doi: <https://doi.org/10.1016/j.urology.2016.11.002>
7. **He J, Ning F, Tu L, Hu J, Chen W, Zhao Y.** Eosinophilic cystitis in children: A case report. *Exp Ther Med.* 2018;16(4). <https://doi.org/10.3892/etm.2018.6578>
8. **Zaman SR, Vermeulen TL, Parry J.** Eosinophilic cystitis: treatment with intravesical steroids and oral antihistamines. *Case Reports.* 2013;2013:bcr2013009327. doi: <http://dx.doi.org/10.1136/bcr-2013-009327>
9. **Luo Y-B, Gao Q, Guo J, Zhang Y, Sun J, Li W-Y, et al.** Ultrasound-guided co-axial introducer needle biopsy in the diagnosis of eosinophilic cystitis in children. *Chinese Medical Journal.* 2021;134(15):1872–3. doi: <https://doi.org/10.1097/cm9.0000000000001564>
10. **Runge SB, Høyer S, Winding L.** Macroscopic Hematuria and a Bladder Mass: Eosinophilic Cystitis in a 7-Year-Old Boy. *Case Reports in Radiology.* 2016;2016:1–4. doi: <https://doi.org/10.1155/2016/9346218>
11. **Sparks S, Kaplan A, DeCambre M, Kaplan G, Holmes N.** Eosinophilic cystitis in the pediatric population: A case series and review of the literature. *Journal of Pediatric Urology.* 2013;9(6):738–44. doi: <https://doi.org/10.1016/j.jpurol.2012.11.004>