



The clinical role of the diagnostic ureteroscopy in upper urinary tract urothelial carcinoma (UTUC): Is it worth using it?

El papel clínico de la ureteroscopia diagnóstica en el carcinoma urotelial del tracto urinario superior (UTUC): ¿vale la pena utilizarla?

Juan Camilo Álvarez,¹ Herney Andrés García-Perdomo.^{2*}

Abstract

Upper urinary tract urothelial carcinoma (UTUC) is a rare pathology representing 5-10% of urothelial carcinomas. The diagnosis is based on images (computed tomography urography or magnetic resonance urography) and urinary cytology, with good diagnostic accuracy. In doubtful cases, diagnostic ureteroscopy allows histopathologic confirmation, better staging, and identifying candidates for kidney-sparing surgery. The objective was to describe the role of diagnostic ureteroscopy and its clinical relevance on patients with suspicion of UTUC. We present a non-systematic review in Pubmed, including additional sources because of their relevance.

Regarding clinical studies, CT or RMN urography has a sensitivity and specificity of >90% with a limitation to identifying flat lesions. Urinary cytology has a detection rate ranging from 43-91% between sampling methods. Optical diagnosis, selective cytology, and biopsy are used when using diagnostic ureteroscopy. The most used tools are optic fiber flexible ureteroscope, flat-wire baskets, and cup biopsy forceps.

Ureteroscopy might decrease de Radical Nephroureterectomy (RNU) rate and misdiagnosis with histopathological confirmation. It also delays the time to RNU and increase of Intravesical recurrence (IVR) without compromising oncological outcomes (OS, CSS, MFS, RFS). The diagnostic ureteroscopy is a valuable tool in UTUC when clinical uncertainty.

Keywords:

Upper tract urothelial carcinoma, diagnostic ureteroscopy, diagnosis, outcomes

Corresponding author:

*Herney Andrés García-Perdomo, Adress: Cll 4B #36-00, Cali, Colombia.
Email: herney.garcia@correounivalle.edu.co

Citation: Álvarez J. C., García-Perdomo H. A. *The clinical role of the diagnostic ureteroscopy in upper urinary tract urothelial carcinoma (UTUC): Is it worth using it?* *Rev Mex Urol.* 2023;83(4):pp 1-9

¹ Universidad Nacional de Colombia, Bogotá, Colombia.

² Grupo de Investigación UROGIV. Escuela de Medicina. Universidad del Valle. Cali, Colombia.

Received: 29 de enero de 2023

Accepted: 27 de agosto de 2023



Resumen

El carcinoma urotelial del tracto urinario superior (UTUC) es una patología rara que representa del 5 al 10% de los carcinomas uroteliales. El diagnóstico se basa en imágenes (urografía por tomografía computarizada o urografía por resonancia magnética) y citología urinaria, con buena precisión diagnóstica. En casos dudosos, la ureteroscopia diagnóstica permite la confirmación histopatológica, una mejor estadiificación e identificación de candidatos a cirugía conservadora de riñón. El objetivo fue describir el papel de la ureteroscopia diagnóstica y su relevancia clínica en pacientes con sospecha de UTUC. Presentamos una revisión no sistemática en PubMed, incluyendo fuentes adicionales por su relevancia.

En cuanto a los estudios clínicos, la urografía por TC o RMN tiene una sensibilidad y especificidad >90% con limitación para identificar lesiones planas. La citología urinaria tiene una tasa de detección que oscila entre el 43 y el 91% entre los métodos de muestreo. Cuando se utiliza ureteroscopia diagnóstica, se utilizan diagnóstico óptico, citología selectiva y biopsia. Las herramientas más utilizadas son el ureteroscopio flexible de fibra óptica, las cestas de alambre plano y las pinzas para biopsia en copa.

La ureteroscopia podría disminuir la tasa de nefroureterectomía radical (RNU) y los diagnósticos erróneos con confirmación histopatológica. También retrasa el tiempo hasta la RNU y aumenta la recurrencia intravesical (IVR) sin comprometer los resultados oncológicos (OS, CSS, MFS, RFS). La ureteroscopia diagnóstica es una herramienta valiosa en UTUC cuando hay incertidumbre clínica.

Palabras clave:

Carcinoma urotelial del tracto superior, ureteroscopia diagnóstica, diagnóstico, resultados

Introduction

Upper urinary tract urothelial carcinoma (UTUC) is a rare pathology representing 5-10% of urothelial carcinomas. The incidence is two cases per 100 000 inhabitants, with predominance in the elderly (70-90 years) and men (2:1 relation with women). Pyelocalyceal compromise is more common than ureteral, and up to 20% are multifocal.⁽¹⁾

The clinical presentation is 3-25% as a recurrence from bladder urothelial carcinoma, 17% synchronous with bladder compromise, and 11-36% with concomitant carcinoma *in situ* (CIS).^(2,3) The diagnosis is based on images (computed tomography urography or magnetic resonance urography) and urinary cytology, with good diagnostic performance.⁽⁴⁻⁶⁾ In the cases where this is insufficient, diagnostic ure-

teroscopy allows histopathologic confirmation, better staging, and identifying candidates for kidney-sparing surgery (low risk according to EAU 2022) and neoadjuvant chemotherapy. The standard treatment for UTUC is radical nephroureterectomy (RNU) with a bladder cuff.⁽¹⁾ The objective is to describe the role of diagnostic ureteroscopy and its clinical relevance on patients with suspicion of UTUC.

Methods

We searched in PubMed, using unique combinations of keywords: upper tract urothelial carcinoma, diagnostic ureteroscopy, diagnosis, and outcomes. Publications in English were included, excluding editor letters and case reports.

We first reviewed titles and abstracts to identify articles for complete text review. EAU guidelines of 2022 and additional studies were included because of their relevance to the topic.

Image and cytology diagnosis

Images in UTUC have excellent performance, and the best diagnostic accuracy is provided by the urography by computed tomography (CT) with a sensitivity of 92% and specificity of 95%. Urography by resonance has less diagnostic performance. However, it can provide up to 95% of sensibility (<2 cm lesions), with a publication that concludes that has no difference ($p>0.05$) in terms of sensibility, specificity, and predictive values compared with retrograde pyelography and diagnostic ureteroscopy. All images have limitations in identifying flat lesions.⁽⁴⁻⁶⁾ Gallioli *et al.* identified the PPV

for UTUC of the different findings in the CT: filling defect 87.7%, thickening 69.6%, and hydronephrosis 79.7%.⁽⁷⁾

A preoperative multivariable model identified ipsilateral hydronephrosis as a predictor of muscle-invasive UTUC with HR 12 (CI 5.1-28.2; $p<0.001$) and of non-organ confined disease with HR 5.1 (CI 2.3- 11.5; $p<0.001$). This model also identified that hydronephrosis plus a positive cytology and high grade (HG) on ureteroscopy biopsy has a negative predictive value of 100%.⁽⁸⁾

Urinary cytology has a detection rate that varies between sampling methods; the barbotage sample is the ideal one with 91%. Other techniques like spontaneous micturition have a 67-76% and ureteral selective sample 43-78% detection rate.⁽⁹⁾

“No-touch technique” and equipment

Unlike other contexts, the “no-touch technique” is described in ureteroscopy as a diagnostic or therapeutic tool. Retrograde insertion of the ureteroscope is made through a transurethral approach, the ureteral meatus of the renal unit involved is identified, and a careful endoscopic inspection is completed. Other steps and unique features in a ureteroscopy for a UTUC patient are: the advance of the guidewire is made under direct vision (unlike ureteroscopy for urolithiasis management), the selective cytology that must be taken on the ureter or renal pelvis ureteral sheath usage is avoided if possible and urothelial lesions are treated individually and immediately as they are identified with the passage of the ureteroscope. All these precautions are based on preserving the yield of the biopsies and the anatomy and preventing

disruption of lesions.⁽¹⁰⁾ The tools that are more used for diagnostic ureteroscopy are the optic fiber flexible ureteroscope (for therapeutics, predominate de use of digital ureteroscope), flat-wire basket and cup biopsy forceps (3Fr and 6 Fr).^(9,11,12)

Ureteroscopy, steps, and diagnostic performance

During the ureteroscopy, the biopsy of suspicious lesions helps confirm histopathology. These samples may be taken generally by basket or cup biopsy; the laser must be used if available (Ho: YAG or Nd: YAD) for hemostasis or when a kidney-sparing treatment is planned to achieve deeper excision.⁽¹⁰⁾

The accuracy of biopsy to determine the tumoral grade is 92.6%, having a better concordance with HG tumors than LG (97 vs. 66%). Concordance of biopsy with final pathology (nephroureterectomy or ureterectomy sample) staging if 43% with a positive predictive value in tumors \geq cT1 of 94% and in \geq cT2 with HG 60%; in the same way, negative predictive value for cTa-cT1S is 60% and <cT2 with LG of 77%. Substaging can reach up to 46-57% of the cases.^(11,13-15)

Tumor grade on ureteroscopy was identified in a multivariable model for prediction with an HR of 16.6 (CI 7.0-39.4, $p < 0.001$) for HG UTUC and with an HR 3.8 (CI 2.1-6.8, $p < 0.001$) with muscle-invasive UTUC on final pathology.⁽¹⁶⁾

Even though the biopsy volume was identified as a possible limitation for the pathologist, a uni and multivariable analysis from 51 cases with UTUC did not find a relationship between the biopsy volume and the agreement with the final tumor grade or stage ($p > 0.05$). This same

study found that the presence of subepithelial connective tissue in the biopsy sample was related to disagreement with the final stage pathology ($p < 0.05$).^(13,17)

Optical diagnosis

Different optical techniques in ureterorenoscopy have been investigated in UTUC, including optical coherence tomography, narrow band imaging (NBI), SPIES (Storz professional image enhancement system), PDD (photodynamic diagnosis), and CLE (confocal laser endomicroscopy). All are under investigation; NBI has been identified to detect 22.7% more tumors in ureteroscopy than in white light.⁽¹⁸⁾ Also, CLE, based on ultrahigh resolution microscopy, has proven a high correlation between the visual evaluation and tumoral grade (low grade 100%, HG 83%, CIS 100%).⁽¹⁹⁾

Ureteroscopy in the diagnostic pathway of UTUC

One study reported that if ureteroscopy were included in the diagnostic and therapeutic pathway of UTUC management, it would change up to 23.7% of medical decisions, achieving endoscopic treatment in 14% of the patients. In high-risk UTUC by image after ureteroscopy, 53.3% had no other surgical indication.⁽⁷⁾

Golan *et al.* determined that ureteroscopy can spare 42% of the patients with suspected UTUC, half were ruled out, and others were managed endoscopically during the endoscopic diagnosis.⁽²⁰⁾ In the same way, Tsivian *et al.* recognized that routine diagnostic ureteroscopy compared without its use, appeared to decrease

the RNU rate (69% vs. 89%) and misdiagnosis (2.1% vs. 15.5%).⁽²¹⁾

Differential diagnosis

The differential diagnosis of UTUC is extensive, including reactive urothelium, papillomas, fibroepithelial polyps, Von Brunn nests, nephrogenic adenoma, PUNLMP, squamous carcinoma, and adenocarcinoma. From personal experience based on two in-press case reports anecdotally renal tuberculosis (Indian Journal of Tuberculosis) and metanephric adenoma (Case Reports).^(17,22)

In a series of 76 cases suspected to have UTUC by filling defect or urothelial thickening, the biopsies report: 32.9% benign urothelium, 22.4% atypical (cannot exclude low-grade urothelial neoplasm), low-grade (LG) urothelial carcinoma 13.2%, HG urothelial carcinoma 10.5%, carcinoma in situ 4% and others. They found significant discrepancies when reviewing the biopsies between two pathologists; seven reports that were initially considered urothelial carcinoma were reclassified as benign lesions (benign urothelium, polypoid pyelitis, polypoid ureteritis, reactive urothelium) by a genitourinary pathologist expert that was reconfirmed as the former on follow up.⁽¹⁷⁾

Clinical implications

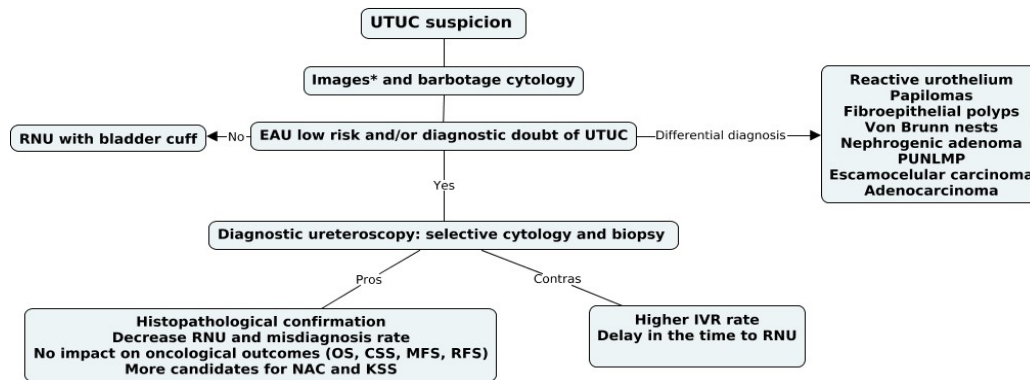
Nison *et al.* concluded that ureteroscopy could delay the time RNU (79.5 vs. 44.5 days, $p=0.04$) without affecting the oncological outcomes.⁽²³⁾ Time from urography to RNU was also longer in patients with diagnostic ureteroscopy (86 vs. 59 days; $p=0.04$).⁽²⁴⁾ Gurbuz *et al.* did not

find a difference in the 5-year recurrence-free survival (72 vs. 69; $p=0.17$) or cancer-specific survival (77 vs. 73%; $p=0.36$) between those who were managed first with diagnostic and therapeutic ureteroscopy before de RNU (compared with those who do not).⁽²⁵⁾ Hendin *et al.*, with the experience of 96 patients, determined that ureteroscopy was not a risk factor for metastasis development, death from metastases, metastasis-free survival, and overall survival ($p>0.05$).⁽²⁶⁾

Some studies have established a relationship between diagnostic ureteroscopy and intravesical recurrence after RNU.^(24,27,28) A Cox regression multivariable analysis reported an HR of 1.59 for diagnostic ureteroscopy (CI 1.14-2.21; $p=0.006$) for intravesical recurrence.⁽²⁸⁾ Yoo *et al.* found that it was a risk factor for IVR, particularly in renal pelvic (HR, 1.98; $p = 0.020$) but not for ureteral tumors (HR, 1.35; $p = 0.071$).⁽²⁹⁾ A systematic review and meta-analysis describe that diagnostic ureteroscopy without biopsy did not lead to a greater risk of IVR (HR 1.28 IC 0.90-1.8; $p=0,16$).⁽³⁰⁾

Even though ureteroscopy is a minimally invasive procedure, it is not harmless, and because of the low prevalence of UTUC, we extrapolate complications from retrograde intrarenal surgery (more commonly, urolithiasis). Common intraoperative complications include ureteric wall injuries from ureteral sheath insertion in 86.6%, ureteral trauma PULS grade 0 in 43%, PULS 1 in 44%, and PULS 2 in 13%.^(31,32) Other complications are not expected (<5%), but the CROES reported perforation in 1.05% and conversion to open surgery in 0.16%.^(33,34) Based on the available literature, we propose the following diagnostic algorithm (figure 1).

Figure 1. Diagnostic algorithm and role of diagnostic ureteroscopy



UTUC: Upper tract urinary carcinoma, RNU: radical nephroureterectomy, PUNLMP: Papillary Urothelial Neoplasm of Low Malignant Potential, OS: Overall survival, CSS: Cancer-specific survival, MFS: metastasis-free survival, RFS: Recurrence-free survival, NAC: neoadjuvant chemotherapy, KSS: kidney sparing surgery, IVR: intravesical recurrence. Images*: Tomography computed urography or urography by resonance.

Conclusion

The diagnostic ureteroscopy is helpful in UTUC when diagnosing uncertainty or by medical criteria. Improving the histopathological confirmation and reducing the misdiagnosis rate can aid physicians in preserving renal units and determining candidates for kidney-sparing surgery (preventing unnecessary RNU). Even in the case of confirmation of UTUC, neoadjuvant chemotherapy may be applied in more FIT patients with two renal units and a better glomerular filtration rate. More studies are needed to evaluate its applicability and convenience in the diagnostic pathway of UTUC.

Conflict of interest

None of the authors have any conflicts of interest or financial ties to disclose.

Funding

This research received no specific grant from any funding agency in the public, commercial, or not-for-profit sectors.

References

1. **European Association of Urology.** EAU Guidelines on Upper Urinary Tract Urothelial Cell Carcinoma. European Association of Urology; 2022.
2. **Inman BA, Tran V-T, Fradet Y, Lacombe L.** Carcinoma of the upper urinary tract: predictors of survival and competing causes of mortality. *Cancer.* 2009;115(13):2853–62. doi: <https://doi.org/10.1002/cncr.24339>
3. **Baard J, Cormio L, Cavadas V, Alcaraz A, Shariat SF, de la Rosette J, et al.** Contemporary patterns of presentation, diagnostics and management of upper tract urothelial cancer in 101 centres: the Clinical Research Office

- of the Endourological Society Global upper tract urothelial carcinoma registry. *Curr Opin Urol.* 2021;31(4):354–62. doi: <https://doi.org/10.1097/mou.0000000000000899>
4. **Gallioli A, Breda A, Boissier R, Territo A, Gaya JM, Martínez MJ, et al.** PT360 - The crucial role of ureteroscopy in the diagnostic/therapeutic pathway of upper tract urothelial carcinoma. *European Urology Supplements.* 2019;18(1):e2161. doi: [https://doi.org/10.1016/S1569-9056\(19\)31561-1](https://doi.org/10.1016/S1569-9056(19)31561-1)
 5. **Lee KS, Zeikus E, DeWolf WC, Rofsky NM, Pedrosa I.** MR urography versus retrograde pyelography/ureteroscopy for the exclusion of upper urinary tract malignancy. *Clin Radiol.* 2010;65(3):185–92. doi: <https://doi.org/10.1016/j.crad.2009.11.003>
 6. **Malm C, Grahn A, Jaremko G, Tribukait B, Brehmer M.** Diagnostic accuracy of upper tract urothelial carcinoma: how samples are collected matters. *Scand J Urol.* 2017;51(2):137–45. doi: <https://doi.org/10.1080/21681805.2017.1295102>
 7. **Gallioli A, Territo A, Mercadé A, Fontana M, Boissier R, Gaya JM, et al.** The Impact of Ureteroscopy following Computerized Tomography Urography in the Management of Upper Tract Urothelial Carcinoma. *J Urol.* 2021 Feb;205(2):392–9. doi: <https://doi.org/10.1097/JU.0000000000001370>
 8. **Brien JC, Shariat SF, Herman MP, Ng CK, Scherr DS, Scoll B, et al.** Preoperative hydronephrosis, ureteroscopic biopsy grade and urinary cytology can improve prediction of advanced upper tract urothelial carcinoma. *J Urol.* 2010;184(1):69–73. doi: <https://doi.org/10.1016/j.juro.2010.03.030>
 9. **Territo A, Gallioli A, Meneghetti I, Fontana M, Huguet J, Palou J, et al.** Diagnostic ureteroscopy for upper tract urothelial carcinoma: friend or foe? *Arab Journal of Urology.* 2021;19(1):46–58. doi: <https://doi.org/10.1080/2090598X.2021.1883810>
 10. **Smith JA, Howards SS, Preminger GM, Dmochowski RR.** *Hinman's Atlas of Urologic Surgery E-Book.* 4th ed. Elsevier Health Sciences; 2016. 1011 p.
 11. **Subiela JD, Territo A, Mercadé A, Balañà J, Aumatell J, Calderon J, et al.** Diagnostic accuracy of ureteroscopic biopsy in predicting stage and grade at final pathology in upper tract urothelial carcinoma: Systematic review and meta-analysis. *European Journal of Surgical Oncology.* 2020;46(11):1989–97. doi: <https://doi.org/10.1016/j.ejso.2020.06.024>
 12. **Soria F, Laguna MP, Roupret M, Garcia-Marchinena P, Gonzalez MS, Habuchi T, et al.** Flexible fibre optic vs digital ureteroscopy and enhanced vs unenhanced imaging for diagnosis and treatment of upper tract urothelial carcinoma (UTUC): results from the Clinical Research Office of the Endourology Society (CROES)-UTUC registry. *BJU Int.* 2021;128(6):734–43. doi: <https://doi.org/10.1111/bju.15494>
 13. **Partin AW., Dmochowski RR, Kavoussi LR, Peters CA, Wein AJ, editors.** *Campbell Walsh Wein Urology: 3-Volume Set.* 12th edition. Philadelphia: Elsevier; 2020. 4096 p.
 14. **Tavora F, Fajardo DA, Lee TK, Lotan T, Miller JS, Miyamoto H, et al.** Small endoscopic biopsies of the ureter and renal pelvis: pathologic pitfalls. *Am J Surg Pathol.* 2009;33(10):1540–6. doi: <https://doi.org/10.1097/pas.0b013e3181aec42a>
 15. **Rojas CP, Castle SM, Llanos CA, Santos Cortes JA, Bird V, Rodriguez S, et al.** Low biopsy volume in ureteroscopy does not affect tumor biopsy grading in upper tract urothelial carcinoma. *Urol Oncol.* 2013;31(8):1696–700. doi: <https://doi.org/10.1016/j.urolonc.2012.05.010>
 16. **Smentkowski KE, Bagley DH, Hubosky SG.**

- Ureteroscopic biopsy of upper tract urothelial carcinoma and role of urinary biomarkers. *Translational Andrology and Urology*. 2020;9(4):1809814–1801814. doi: <https://doi.org/10.21037/tau.2019.11.28>
17. **Fojecki G, Magnusson A, Traxer O, Baard J, Osther PJS, Jaremko G, et al.** Consultation on UTUC, Stockholm 2018 aspects of diagnosis of upper tract urothelial carcinoma. *World J Urol*. 2019;37(11):2271–8. doi: <https://doi.org/10.1007/s00345-019-02732-8>
 18. **Clements T, Messer JC, Terrell JD, Herman MP, Ng CK, Scherr DS, et al.** High-grade ureteroscopic biopsy is associated with advanced pathology of upper-tract urothelial carcinoma tumors at definitive surgical resection. *J Endourol*. 2012;26(4):398–402. doi: <https://doi.org/10.1089/end.2011.0426>
 19. **Bus MTJ, de Bruin DM, Faber DJ, Kamphuis GM, Zondervan PJ, Laguna Pes MP, et al.** Optical Diagnostics for Upper Urinary Tract Urothelial Cancer: Technology, Thresholds, and Clinical Applications. *Journal of Endourology*. 2015;29(2):113–23. doi: <https://doi.org/10.1089/end.2014.0551>
 20. **Breda A, Territo A, Guttilla A, Sanguedolce F, Manfredi M, Quaresima L, et al.** Correlation Between Confocal Laser Endomicroscopy (Cellvizio®) and Histological Grading of Upper Tract Urothelial Carcinoma: A Step Forward for a Better Selection of Patients Suitable for Conservative Management. *Eur Urol Focus*. 2018;4(6):954–9. doi: <https://doi.org/10.1016/j.euf.2017.05.008>
 21. **Golan S, Nadu A, Lifshitz D.** The role of diagnostic ureteroscopy in the era of computed tomography urography. *BMC Urology*. 2015 Jul 25;15(1):74. doi: <https://doi.org/10.1186/s12894-015-0068-8>
 22. **Tsivian A, Tsivian M, Stanevsky Y, Tavdy E, Sidi AA.** Routine Diagnostic Ureteroscopy for Suspected Upper Tract Transitional-Cell Carcinoma. *Journal of Endourology*. 2014 Aug;28(8):922–5. doi: <https://doi.org/10.1089/end.2013.0703>
 23. **Nison L, Rouprêt M, Bozzini G, Ouzzane A, Audenet F, Pignot G, et al.** The oncologic impact of a delay between diagnosis and radical nephroureterectomy due to diagnostic ureteroscopy in upper urinary tract urothelial carcinomas: results from a large collaborative database. *World J Urol*. 2013;31(1):69–76. doi: <https://doi.org/10.1007/s00345-012-0959-1>
 24. **SHSM H, Bright E, Mantle M, Munro N, Fahmy O.** Diagnostic Ureteroscopy in CT Urography-Diagnosed Upper Tract Urothelial Carcinoma: Delay in Definitive Treatment and Increased Intravesical Recurrence. *Cureus*. 2021;13(6):e15775. doi: <https://doi.org/10.7759/cureus.15775>
 25. **Gurbuz C, Youssef RF, Shariat SF, Lotan Y, Wood CG, Sagalowsky AI, et al.** The Impact of Previous Ureteroscopic Tumor Ablation on Oncologic Outcomes After Radical Nephroureterectomy for Upper Urinary Tract Urothelial Carcinoma. *Journal of Endourology*. 2011;25(5):775–9. doi: <https://doi.org/10.1089/end.2010.0396>
 26. **Ishikawa S, Abe T, Shinohara N, Harabayashi T, Sazawa A, Maruyama S, et al.** Impact of Diagnostic Ureteroscopy on Intravesical Recurrence and Survival in Patients With Urothelial Carcinoma of the Upper Urinary Tract. *Journal of Urology*. 2010;184(3):883–7. doi: <https://doi.org/10.1016/j.juro.2010.05.027>
 27. **Sung HH, Jeon HG, Han DH, Jeong BC, Seo SI, Lee HM, et al.** Diagnostic Ureterorenoscopy Is Associated with Increased Intravesical Recurrence following Radical

- Nephroureterectomy in Upper Tract Urothelial Carcinoma. *PLoS One*. 2015;10(11):e0139976. doi: <https://doi.org/10.1371/journal.pone.0139976>
28. Liu P, Su X-H, Xiong G-Y, Li X-S, Zhou L-Q. Diagnostic Ureteroscopy for Upper Tract Urothelial Carcinoma is Independently Associated with Intravesical Recurrence after Radical Nephroureterectomy. *Int Braz J Urol*. 2016;42(6):1129–35. doi: <https://doi.org/10.1590/s1677-5538.ibju.2015.0366>
29. Yoo S, You D, Song C, Hong B, Hong JH, Kim C-S, et al. Risk of Intravesical Recurrence After Ureteroscopic Biopsy for Upper Tract Urothelial Carcinoma: Does the Location Matter? *J Endourol*. 2017;31(3):259–65. doi: <https://doi.org/10.1089/end.2016.0611>
30. Nowak Ł, Krajewski W, Chorbińska J, Kielb P, Sut M, Moschini M, et al. The Impact of Diagnostic Ureteroscopy Prior to Radical Nephroureterectomy on Oncological Outcomes in Patients with Upper Tract Urothelial Carcinoma: A Comprehensive Systematic Review and Meta-Analysis. *Journal of Clinical Medicine*. 2021 Jan;10(18):4197. doi: <https://doi.org/10.3390/jcm10184197>
31. Schoenthaler M, Buchholz N, Farin E, Ather H, Bach C, Bach T, et al. The Post-Ureteroscopic Lesion Scale (PULS): a multicenter video-based evaluation of inter-rater reliability. *World J Urol*. 2014;32(4):1033–40. doi: <https://doi.org/10.1007/s00345-013-1185-1>
32. Traxer O, Thomas A. Prospective evaluation and classification of ureteral wall injuries resulting from insertion of a ureteral access sheath during retrograde intrarenal surgery. *J Urol*. 2013;189(2):580–4. doi: <https://doi.org/10.1016/j.juro.2012.08.197>
33. Baş O, Tuygun C, Dede O, Sarı S, Çakıcı MÇ, Öztürk U, et al. Factors affecting complication rates of retrograde flexible ureterorenoscopy: analysis of 1571 procedures—a single-center experience. *World J Urol*. 2017;35(5):819–26. doi: <https://doi.org/10.1007/s00345-016-1930-3>
34. Somani BK, Giusti G, Sun Y, Osther PJ, Frank M, De Sio M, et al. Complications associated with ureterorenoscopy (URS) related to treatment of urolithiasis: the Clinical Research Office of Endourological Society URS Global study. *World J Urol*. 2017;35(4):675–81. doi: <https://doi.org/10.1007/s00345-016-1909-0>